

Ultrasonographic study of equine eyes

E. Svaldenienė, M. Paunksnienė, V. Babrauskienė

Department of Anatomy and Physiology, Lithuanian veterinary academy

Tilžės 18, Kaunas, Lithuania

Introduction

Acutely blind horses are extremely agitated, anxious and dangerous. The horse has a large and prominent eyeball. Some ocular diseases such as microphthalmos, cataract, corneal ulceration, tumors are very common for the horses and requiring early clinical diagnosis. Ultrasonography allows to evaluate the state of the globe and internal structure regardless of opacities in the anterior segment and lens without any stress for patients (Brooks, 2002; Barnett, Crispin et al., 1995). Cataract is the most frequent congenital ocular defect for foals. In adult horses cataract may be as result of ether uveitis and trauma. Ultrasonography is recommended as screening tool for surgical candidates as can verify the stage and location of a cataract (Scotty, Cutler et al., 2004). Ultrasonography can be provided for diagnosis of many diseases involving cornea, aqueous humor and vitreous. Ultrasound biometry was recognized as an efficient anatomical tool useful in studying eye size or in detecting changes of an ocular axial length between myopic and hypermyopic eye (Sanchis gimeno, Alonso et al., 2002; Cegarra, Casanova Izquierdo et al., 2001).

The data about horses' corneal thickness, size and shape varied in different authors. Some of them reported that central cornea was thinner than peripheral (Prince et al, 1960; van der Woerd, Gilger et al, 1995), other said that central cornea was thicker than peripheral (Gelatt, 1981). Using ultrasonic pachymetry it was diagnosed that horses with cornea globosa had significantly thicker cornea in the central and temporal peripheral portions compare with those that were clinically normal. There were no differences in the corneal thickness between male and female or between left and right eye, but there was a positive correlation between age and corneal thickness (Ramsey, Hauptman et al, 1999). Corneal sensitivity varied as well as corneal thickness and the central corneal region being the most sensitive (Kaps, Richter, Spiess, 2003).

The aim of this study was to measure and compare parameters of the eye in different age horses, to analyze corneal thickness mapping using ultrasonic pachymetry.

Materials and methods

We used 23 equine eyes in our study. We measured 10 eyes of the 1-4 months-old foals, 4 eyes of 9-10 year-old horses, 5 eyes of 19-20 year-old horses, 4 eyes of 30-35 year-old horses. After death all eyes were immediately enucleated and measured using A-type ultrasonographic technique. The length of sagittal eye axis, the thickness of anterior eye segment (from anterior corneal surface to anterior lens surface), the thickness of the lens and vitreous

were measured. Four eyes of the adult horses were used in a corneal thickness mapping study. Using ultrasonic pachymetry thickness of the cornea was measured the 13 points. We measured thickness in central, peripheral superior, peripheral inferior, peripheral nasal and peripheral temporal, peripheral nasoinferior, nasosuperior, temporoinferior and temporosuperior points and nasocentral, temporo-central, superio-central and inferio-central points (Fig. 1). Temporal points were taken 1 mm from limbus. The central point was in the center of the cornea; other 4 points were taken in the middle between central and superior, inferior, temporal and central points. 4 measurements were made at each point and the average of these measurements was referred as one measurement.

Results

All eye parameters were smaller in foals than in adult horses, except the anterior eye segment that was thinner in 30-35 year-old horses than foals. Thickness of the anterior eye segment varied in adult horses: it was the biggest in 9-10 year-old horses and the smallest in 19-20 year-old horses. We found that foals had thinner lens than adult horses and it placed more anteriorly than in adult ones: the thickness of anterior eye segment (length from cornea to anterior lens surface) was less in foals than in adult horses of 9-20 year-old. The thickness of the lens reduced with age: 9-10 year-old horses had the thickest lens. Foals had smaller vitreous than adult horses. The vitreous was the thickest in 19-20 year-old horses. Thickness of the vitreous in 9-10 year-old and 30-35 year-old horses was very similar: respectively 24.08 mm and 24.05 mm. The length of sagittal eyeball axis was biggest in 19-20 year-old horses. 9-10 year-old and 30-35 year-old horses had a shorter sagittal eyeball axis. Foals had a shorter sagittal eyeball axis than adult horses (Table 1).

The anterior segment in foals constituted 17%, lens – 26% and vitreous – 57% of sagittal eye ball axis. In 9-10 years-old horses these percent were similar: anterior segment took 16%, lens – 27%, and vitreous – 57%. In 19-20 years-old horses anterior segment took 14%, lens percentage was the same as in 9-10 year-old horses, and vitreous reached 59%. In 30-35 year-old horses lens constituted less percentage in all group – only 23%, anterior segment was similar as in other groups – 15% and vitreous reached the biggest percentage in all groups – 62%.

Analysis of corneal thickness in different cornea points showed that the central part of the cornea was the thinnest – 814.6 μm . Paracentral part (CN, CT, CS and CI points) was thicker than the central point but thinner than

peripheral points. The corneal thickness differed from 846.1 to 868.9 μm. All peripheral points were thicker than the central and paracentral parts of the cornea. Thickness of a peripheral part differed from 887 μm at the peripheral temporal point to 917.3 μm at the peripheral superior

point. Corneal thickness was the biggest superior region of the cornea (Table 2).

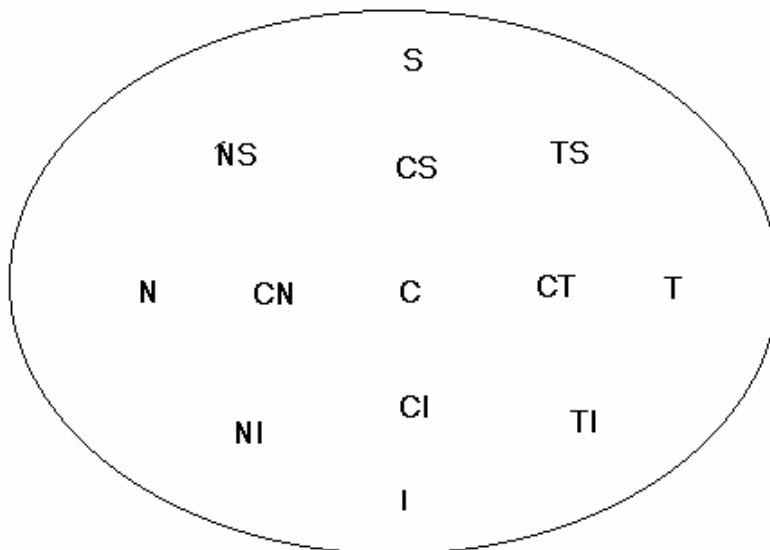


Fig. 1. Points of the corneal thickness measurements

C – central, S - peripheral superior, I – peripheral inferior, N – peripheral nasal, T – peripheral temporal, NI – peripheral nasoinferior, NS – peripheral nasosuperior, TI – peripheral temporoinferior, TS – peripheral temporosuperior, CN – nasocal, CT – tempocal, CS – superiocal, CI – inferiocal points

Table 1. Parameters of eye structures (mm) in different age horses (average±standard deviation)

Groups of horses	Thickness of anterior eye segment	Lens thickness	Vitreous thickness	Length of sagittal eyeball axis
1-4 month-old foals (n=10)	5.86±0.42	8.87±1.27	18.82±1.47	33.47±2.25
9-10 year-old horses (n=4)	6.93±0.63	11.33±0.65	24.08±1.9	42.63±1.06
19-20 year-old horses (n= 5)	5.58±1.99	10.86±1.51	24.48±0.54	43.1±0.54
30-35 year-old horses (n=4)	6±2.51	9±2.76	24.05±1.78	40.55±2.39

Table 2. Adult horses' corneal thickness (μm) in different corneal regions

	C	S	I	N	T	NI	NS	TI	TS	CN	CT	CS	CI
1.	881.4	923.8	963	963	910.4	909	909	959.4	912.2	945	874.8	913.8	886.6
2.	756.2	873.2	844.4	809.8	812.8	830.4	827	808.6	873.2	759.4	797.2	781.6	788.6
3.	816	958.4	940.2	912.4	936	954.2	948.2	921.4	922.8	846.2	884	860.4	888.8
4.	804.8	913.6	890.6	914.4	888.8	891.4	937.8	940.6	925	854.6	828.4	894.8	911.4
Av.	814.6	917.3	909.6	899.9	887	896.3	905.5	907.5	908.3	851.3	846.1	862.7	868.9
SD	51.55	35.07	52.92	64.46	53.1	51.25	54.9	67.73	24.06	75.86	35.23	58.38	54.66

C – central, S - peripheral superior, I – peripheral inferior, N – peripheral nasal, T – peripheral temporal, NI – peripheral nasoinferior, NS – peripheral nasosuperior, TI – peripheral temporoinferior, TS – peripheral temporosuperior, CN – nasocal, CT – tempocal, CS – superiocal, CI – inferiocal points

Discussion

Ultrasound has been used in ophthalmology since 1956. By using ultrasound information can be obtained on ocular structure since the passage of ultrasonic waves

through different tissues is reflected in generation of distinctive echoes and hence specific information on these tissues can be obtained (Cegarra et al, 2001). Ultrasonography affords the benefit of providing a complete cross-sectional view of the globe (Scotty et al,

References

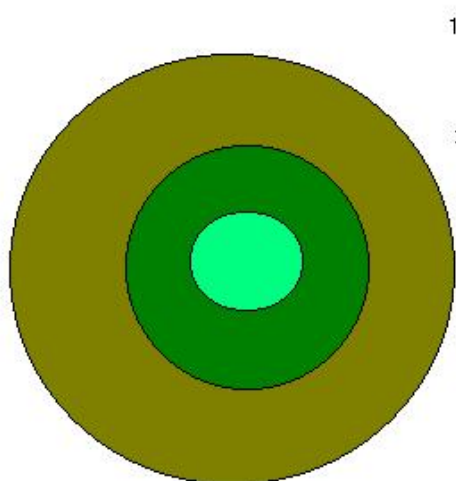


Fig 2. Mapping of corneal thickness in adult horses: 1 – average corneal thickness 814.6 μm ; 2 – average corneal thickness 846.1-868.9 μm ; 3 – average corneal thickness 887.0-917.3 μm

2004). So, the aim of this study was to measure and compare parameters of eye in different age horses. Foals' eyes and their structures were smaller than adult horses although the anterior segment of the eye was thicker than in 19-20 year-old horses. 19-20 year old horses had the thickest vitreous and the sagittal axis length was the biggest in all adult horses' groups. 9-10 year old horses had the thickest anterior eye segment and lens, but vitreous and sagittal axis was smaller than in 19-20 year-old horses eye. We supposed that the sagittal eye axis length depended mainly on the vitreous thickness. Thickness of eye parameters decreased with age and 30-35 year-old horses had thinner lens and vitreous and shorter sagittal eye axis although the percentage of the vitreous was bigger than in younger horses' eyes. Ekesten proposed that the thickness lens of the canine eye increased during the dogs' life (Ekesten, 1994). We found that the lens thickness of the equine eye decreased with age of the horse from 11.33 mm in 9-10 year-old horses to 9.0 mm in 30-35 year-old horses. The decreased lens thickness could result increased thickness of anterior segment in 30-35 year-old horses.

Ultrasonic pachymetry is an accurate method of measuring corneal thickness in horses. Papers on ultrasonic pachymetry indicated that peripheral portion of the cornea was thicker than the central portion. Our study showed the similar corneal thickness mapping. The central part of the cornea was the thinnest, the paracentral part was thicker than the central, but thinner than the peripheral regions. The corneal thickness could be an indirect quantitative measurement of the endothelial cell density and function (Ramsey, 1999). The decreased thickness of the central part of the equine cornea could be due to curvature of the cornea.

1. Barnett K. C., Crispin S. M. et al. Color atlas and text of equine ophthalmology. Mosby-Wolf. 1995. P. 51-58.
2. Brooks D. E. Equine ophthalmology. Teton NewMedia, Jackson. 2002. P. 1-11.
3. Cegarra M. J., Casanova Izquierdo J. et al. Consolidating the anatomical relationship between ocular axial length and spherical equivalent refraction. *Eyr j Anat.* 2001. Vol. 5. P. 145-150.
4. Ekesten B. Primary glaucoma in the Samoyed dog. Dissertation. Uppsala. 1994. P. 43-44.
5. Gelatt K. N. Veterinary ophthalmology. Philadelphia: Lea and Febiger. 1981. P. 23-35.
6. Kaps S., Richter M., Spiess B. M. Corneal esthesiometry in the healthy horse. *Veterinary ophthalmology.* 2003. Vol. 6. P. 151-155.
7. Prince J. H., Diesem C. D. et al. Anatomy and histology of the eye and orbit in domestic animals. Springfield; Charles C. Thomas. 1960. P. 133-134.
8. Ramsey D. T., Hauptman J. G., Petersen-Jones S. M. Corneal thickness, intraocular pressure and optical corneal diameter in Rocky Mountain Horses with cornea globosa or clinically normal cornea. *AJVR.* 1999. Vol. 60. P. 1317-1321.
9. Sanchis Gimeno J. A., Alonso L. et al. Assessment of differences in ocular morphometric measurements by using optical and applanation ultrasound biometry in the same eye. *Eur J Anat.* 2002. Vol. 6. P.127-132.
10. Scotty N. C., Cutler T. J. et al. Diagnostic ultrasonography of equine lens and posterior segment abnormalities. *Veterinary ophthalmology.* 2004. Vol. 7. P.127-139.
11. Van der Woerd A., Gilger B. C. et al. Effect of auriculopalpebral nerve block and intravenous administration of xylazine on intraocular pressure and corneal thickness in horses. *AJVR.* 1995. Vol. 56. P.155-158.

E. Svaldenienė, M. Paunksnienė, V. Babrauskienė

Arklių akių ultragarsinis tyrimas

Reziumė

Šio tyrimo tikslas buvo išmatuoti įvairaus amžiaus arklių akių struktūrų matmenis bei ragenos storį naudojant ultragarsinę aparatūrą. Tirtos 23 įvairaus amžiaus (nuo 1 mėn. iki 35 metų) arklių akys. Matuotas priekinio segmento gylis, lęšio ir stiklakūnio storis bei sagitalinės akies ašies ilgis. 4 suaugusių arklių akių ragenos storis buvo išmatuotas 13 taškų. Nustatyta, kad kumeliukų akių elementai buvo mažiausi, tačiau priekinio akies segmento matmenys buvo didesni negu 19-20 metų arklių. Pastarųjų stiklakūnio storis buvo didžiausias, o visų suaugusių arklių ilgiausia buvo sagitalinė ašis. 9-10 metų arklių priekinis akies segmentas ir lęšis buvo storiausias, bet stiklakūnio ir sagitalinės ašies matmenys buvo mažesni negu 19-20 metų arklių. Ragenos storio analizė parodė, kad centrinė jos dalis buvo ploniausia, paracentrinė dalis buvo storesnė už centrinę, bet plonesnė už periferinę.

Pateikta spaudai 2004 10 11

DOI: 10.5755/j01.u.53.4.16916