

## Ultrasound value in diagnosis, management and prognosis of severe eye injuries

**E. Puodžiuvienė<sup>1,2</sup>, A. Paunksnis<sup>1,2</sup>, S. Kurapkienė<sup>1,3</sup>, D. Imbrasienė<sup>1</sup>**

*1 Institute for Biomedical Research, Kaunas University of Medicine*

*2 Eye Clinic of Kaunas Medical University Hospital*

*3 Kaunas University of Technology*

Serious eye trauma can result in a wide spectrum of tissue lesions of the globe, optic nerve and adnexa, ranging from the relatively superficial to vision threatening. Our understanding of the pathophysiology and management of these disorders has advanced tremendously over the last 10 years. BETT (Birmingham Eye Trauma Terminology), the uniform Ocular Trauma Classification system, World Eye Injury Registry (WEIR), Ocular Trauma Score (OTS) for predicting the final vision in the injured eye were developed and enabled accurate transmission of clinical data, facilitating the delivery of optimal patient care as well as further analysis of the efficacy of medical and surgical interventions.

Although the eyes represent only 0.1% of the total body surface and only 0.27% of the anterior body surface, their significance to individuals and society is disproportionately higher: most information reaches humans through vision. Those affected often have to face loss of career opportunities, major lifestyle changes, and, occasionally, permanent physical disfigurement. In industrialized nations trauma has become the most common reason for extended hospitalization of ophthalmologic patients. In the United States almost 2.5 million incident cases of eye injuries are registered each year. In Sweden they have three eye trauma cases for 100 000 inhabitants per year. The situation in developing countries is much more complicated (e.g. in Lithuania the number of patients with eye trauma is 7 times higher than in Sweden). Eye trauma is the second leading cause of monocular blindness in the world, and the first – in Lithuania.

Kaunas Medical University Hospital is the National Centre of Ophthalmology. 530 – 800 patients with severe ocular injuries from whole Lithuania are treated there annually. More than 250 cases of primary surgery are performed every year. The high concentration of ocular trauma pathology requires not only good skill and experience of ophthalmologists, not only advanced surgery techniques, but modern diagnostic technologies too.

The main imaging techniques used in ophthalmology and ocular traumatology today are CT (computed tomographic scanning), MRI (magnetic resonance imaging) and ultrasonography. Echography as one of the most important studies in ophthalmology provides one- or two-dimensional images displayed in the real time on an oscilloscope screen. Interpretation requires consideration of eye position, probe position, and the knowledge of the echogenic characteristics of ocular and related structures.

The diagnostic ultrasonography utilizes high-frequency sound waves to study the properties of ocular

structures. It is used extensively in evaluation of both the globe and orbit for broad range of conditions, including severe ocular injuries.

Standardized A-scan (amplitude modulation) displays a series of spikes along a baseline. The height of the spikes obtained using this mode correlates with the density of the structure displayed, whereas the distance between spikes corresponds to the distance between structures. This modality makes it possible to differentiate one pathologic process from another.

The most common and useful mode of operation in ophthalmic echography is B-scan (brightness modulation), which provides the generation of two-dimensional section of the eye and orbit. This permits a rapid assessment of location, size, and configuration of any abnormal structures within the globe or orbit. Cross – sections and radial sections of the eye and orbit can be obtained by changing the orientation of the ultrasound probe, thus providing the maximum amount of information about intraocular and orbital pathology.

The Mentor Advent A/B ultrasound system is a typical ophthalmological scanner routinely used for patient eye examinations in Kaunas Eye Clinics. In-vivo examination of eye traumas by Mentor<sup>TM</sup> A/B ultrasonic imaging system (Mentor Advent) is performed using 7 MHz A-mode and 12,5 MHz B-mode probes, velocity of ultrasonic waves – 1550 cm/s, scan range – 50 mm. The A and B-scan image is transferred from a video output of the ultrasonic system to a personal computer (PC) by the use of a frame grabber. Such ultrasound image capture method is quite simple and can be implemented with the most ultrasonic systems. The captured image is of size 640x480 pixels.

The most common use for the B-scan is to assess the posterior segment for pathological findings when the view of the fundus is obscured by media opacities (Table 1).

When ophthalmoscopic evaluation is limited or not possible, the echography is useful in determining and characterising the internal ocular anatomy and detecting IOFBs (intraocular foreign bodies):

- Retinal detachment;
- Posterior vitreous separation;
- Vitreous hemorrhage and opacities;
- Choroidal detachment (can differentiate between serous and hemorrhagic);
- Retinal tears and areas of vitreoretinal adhesions;
- Choroidal and scleral ruptures;
- Vitreous incarceration;
- IOFBs, both radiolucent and radio-opaque.

Table 1. Potential Posterior Segment Findings following Severe Ocular Injury

Findings	Contusion	Laceration	Rupture
Vitreous hemorrhage <sup>U</sup>	Yes	Yes	Yes
Vitreous pigment	Yes	Uncommon	Uncommon
Vitreous base dialysis <sup>U</sup>	Yes	Uncommon	Yes
Retinal flap tear <sup>U</sup>	Yes	Yes	Yes
Posterior vitreous separation <sup>U</sup>	Yes	Uncommon	Yes
IOFB <sup>U</sup>	No	Yes	Uncommon
Comotio retinae <sup>U</sup>	Yes	Uncommon	Uncommon
Macular hole	Yes	Uncommon	Uncommon
Choroidal rupture	Yes	No	Uncommon
Sclopetaria	Yes	No	Yes
Subretinal hemorrhage <sup>U</sup>	Yes	Yes	Yes
Optic nerve avulsion	Yes	Uncommon	Uncommon
Retinal detachment <sup>U</sup>	Uncommon	Uncommon	Yes
Hypotony maculopathy	Yes	Yes	Yes
Lens dislocation <sup>U</sup>	Yes	No	Yes
Endophthalmitis <sup>U</sup>	No	Yes	Uncommon

<sup>U</sup> – findings detected by ultrasound

The ophthalmic ultrasound has several practical advantages compared with CT and MRI:

- Unlike MRI and CT, ultrasound provides real – time images of the eye and orbit.
- The relatively high frequency of the sound waves (10 MHz) affords outstanding resolution (0.1 to 0.01 mm) and ideal choice to image intraocular structures.
- Multiple cross-sectional and radial cuts of the eye can be rapidly obtained at the bedside or in an operating room.
- Serial echography permits following the clinical course of various conditions (e.g., choroidal detachment resolution, membrane or retinal detachment development).
- Ultrasonography is less expensive than radiological studies.
- The equipment needed to perform the echography is easily transportable to a patient's bedside or to an operating room when necessary.

Unfortunately, ultrasonography has some disadvantages:

- Because ultrasound requires a direct contact with the eyelids and/ or globe, it should not be used in eyes with the high risk of extrusion of intraocular contents (e.g., large wound, uncooperative patient). In these cases, echography can be performed in an operating room after the globe has been closed and the patient is under general anesthesia. Thus, a ruptured globe may be a relative contraindication to ultrasound examination,

depending on the severity of the injury and the experience of the ultrasonographer.

- Training and skill are required.
- It is not useful in diagnosing orbital fractures.
- Sometimes there are difficulties in determining size and site of an IOFB.

Ultrasound is the preferred modality of imaging *choroidal detachments* for initial evaluation and follow-up examination. If hemorrhage and blood clot formation occur in the suprachoroidal space, serial ultrasound examinations are useful to monitor the clot for dissolution before a drainage procedure. On B-scan choroidal detachments (Fig. 1) appear as dome-shaped, often bullous lesions that do not extend to the optic disc. They may be localized or involve the entire fundus. On A-scan the choroidal detachment produces a maximally high, thick, double-peaked spike separate from the fundus spikes. The height of the chain of spikes between the surface of the choroid and the sclera is the most reliable indicator of the density of the hemorrhage and clot formation in the suprachoroidal space. A series of tall spikes represents a newly formed clot. A series of low spikes is observed after lysis of the clot.

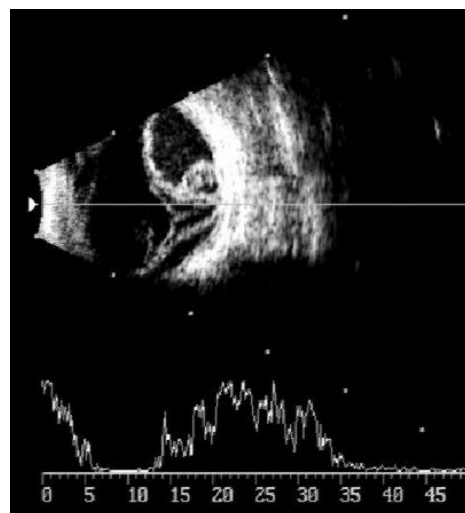


Fig.1. A and B scan ultrasound of serous choroidal detachment

In cases of *endophthalmitis* (Fig.2) patients present with a wide spectrum of ocular signs. The most useful role of echography is documentation of findings at the onset of symptoms and continued follow-up to assess improvement or worsening of the infection. If the fundus cannot be visualised, ultrasound is of critical importance to rule out choroidal detachments before performing a vitreous tap or injection of intravitreal antibiotics. Findings include mild to dense vitreous opacities that appear as mobile echodense condensates; membrane formation that, when located posteriorly, can be difficult to distinguish from a retinal detachment; retinal detachment and choroidal detachment.

Ultrasound is a valuable adjunct to the detection and localization of both metallic and nonmetallic *foreign bodies* (Fig. 3). The resolution depends on the echogenicity of the material; the lower limit of resolution is approximately 0.2 mm in diameter. Foreign bodies in the globe or orbit generally produce an extremely bright signal

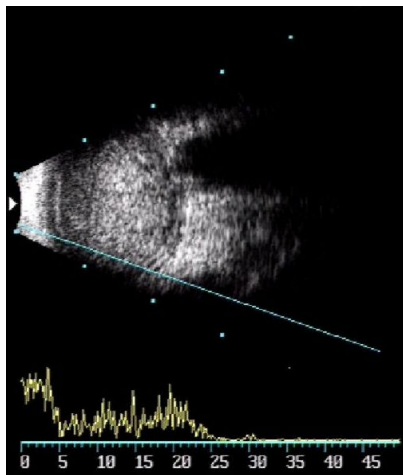


Fig.2. A and B scan ultrasound of endophthalmitis

on B-scan with and associated shadow or comet tail artifact depending on the composition of a foreign body (e.g., cement produces a shadow, round BB produces a comet tail). On a standardized A-scan, foreign bodies produce a single extremely high spike. When an object has perforated the globe both anteriorly and posteriorly, echographically a hemorrhagic tract can be identified extending from the point of entry to the exit site. The fundus near the exit wound is usually markedly thickened, with elevation of adjacent retina. There also can be blood and a hemorrhagic tract through the orbit tissue.

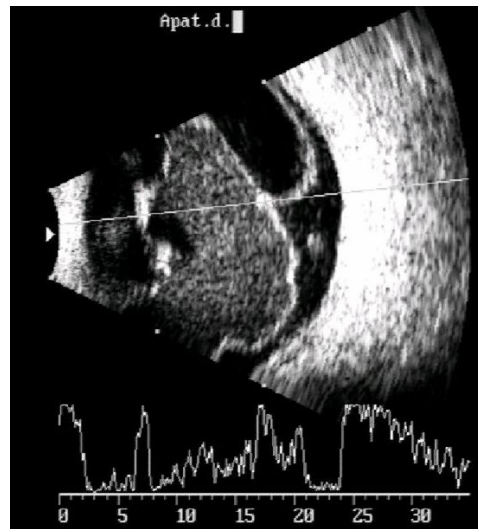


Fig. 4. A and B scan ultrasound of intraocular foreign body.

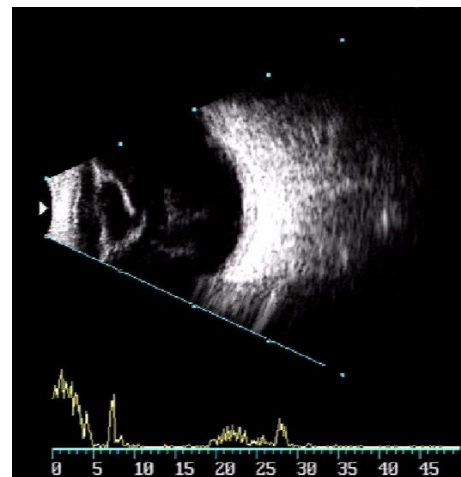


Fig. 5. A and B scan ultrasound of open globe injury

hemorrhages the vitreous cavity may be filled with echoes. Associated findings may include retinal tear, retinal or choroidal detachment, foreign bodies, lens dislocation, scleral rupture, orbital hemorrhage, or fracture.

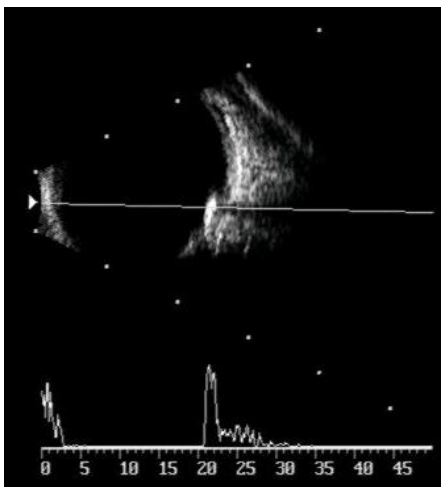


Fig. 3. A and B scan ultrasound of intraocular foreign body

The *detached retina* (Fig. 4) appears as a dense, thick, often folded, slightly mobile continuous membrane that inserts into the optic disc. The retina can be detached in the localized area or totally detached, producing a funnel-shaped membrane. On a standardized A-scan retinal detachments almost always produce a maximally high spike separate from the fundus spikes.

In *open globe injuries* (Fig. 5) findings include an abnormal scleral contour or scleral folds. The rupture or penetration site may be imaged directly as a discontinuity of the sclera, with a hemorrhagic tract in the vitreous leading up to the rupture site.

Acute dispersed *vitreous hemorrhage* (Fig. 6) may be minimally echogenic. In subacute and chronic

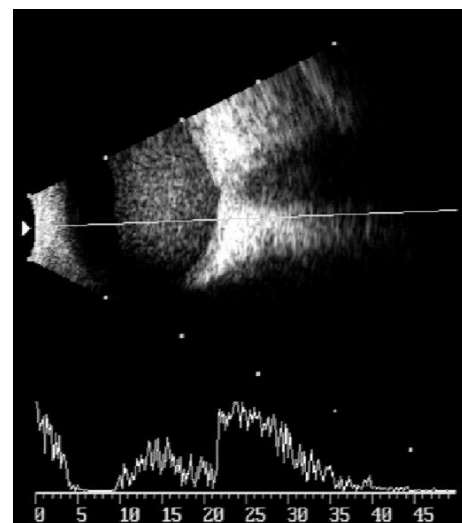


Fig. 6. A and B scan ultrasound of vitreous hemorrhage.

Echography provides excellent images of eye and in the hands of an experienced echographer can provide a reliable and detailed information about the ocular and orbital structures. When ophthalmoscopic evaluation is limited or not possible, echography is useful in determining the density of vitreous opacities and hemorrhage, and the extent of retinal and choroidal detachments. Additionally, ultrasound is reliable in localizing choroidal and scleral rupture sites as well as radio-opaque and radiolucent intraocular and orbital foreign bodies. Orbital structures can be visualized using this modality. Ophthalmic ultrasound has several practical advantages compared with CT and MRI. The equipment needed to perform echography is easily transportable when necessary, making it one of the most efficient and rapid means of diagnostic imaging in many different settings.

#### References

1. **Kuhn F., Pieramici D. J.** Ocular trauma. Principles and practice. 2002. P. 58-61.
2. **Lee D. A., Higginbotham E. J.** Clinical guide to comprehensive ophthalmology. 1999. P. 46 – 48.
3. **Maccumber M. W.** Management of ocular injuries and emergencies. 1998. P. 59 – 75.
4. Mentor Advent A/B ultrasound system. Instruction manual, P/N 2550-4010 Rev.B, 1997 mentor Ophthalmics, Inc.

5. **Jegelevičius D., Lukoševičius A., Paunksnis A., Šebeliauskienė D.** Parameterisation of ultrasonic echographic images for intraocular tumour differentiation. Ultragasas. Nr.1 (42). 2002. P.50-56.

E. Puodžiuvienė, A. Paunksnis, S. Kurapkienė, D. Imbrasienė

#### Ultragarinio tyrimo nauda sunkių akių traumų diagnozei, gydymui ir prognozei

##### Reziumė

Sunkios akių traumos – viena dažniausių vienakio aklumo priežasčių tiek Lietuvoje, tiek visame pasaulyje. Pažymėtina, kad Lietuvoje akių traumų pasitaiko 7 kartus daugiau negu tokiose išsivysčiusiose šalyse kaip, pavyzdžiui, Švedija. Tai – svarbi medicininė, socialinė ir ekonominė problema, dažniausiai paliečianti jauno, darbingo amžiaus žmones. Dėl akių traumų laikinai nebetenkama darbingumo arba tampama regos invalidais. Siekiant to išvengti, Lietuvoje, kaip ir daugelyje šalių, tobulinami akių traumų diagnostikos bei gydymo būdai. Ultragarinis tyrimas – vienas dažniausiai taikomų ir informatyviausių instrumentinių diagnostinių akių sužeidimų bei jų komplikacijų tyrimų. Jis labai svarbus numatant konservatyvaus ar chirurginio gydymo taktiką, padeda numatyti akies sužeidimo pasekmes.

Buvo ištirta 300 ligonių, 2001–2003 m. patyrusių sunkias akių traumas. Remiantis tarptautine akių traumų klasifikavimo sistema, šie ligoniai buvo suskirstyti į grupes pagal sužeidimo rūšį. Ultragarinis tyrimas atliktas 55 proc. ligonių *Mentor Advent A/B* sistema, naudojant 7, 12,5 ir 15 MHz dažnio daviklį. Įvertinus ultragarinio tyrimo naudingumą įvairių rūšių sužeidimams, jis dažniausiai imtas taikyti akies obuolio plyšimų bei sumušimų atvejais. Neabejotinai ultragarinis tyrimas naudingas akies užpakalinio segmento (stiklakūnio, tinklainės) patologinių pokyčių diagnozei.

Pateikta spaudai 2005 09 19

DOI: 10.5755/j01.u.56.3.16942