

## The use of echospectral methods of tissue evaluation for follow-up of brachytherapy treatment

A.Paunksnis<sup>1</sup>, S.Kurapkienė<sup>1</sup>, A.Mačiulis<sup>2</sup>, A.Lukoševičius<sup>3</sup>, M.Špečkauskas<sup>1</sup>

<sup>1</sup>*Dept. of Ophthalmology, Institute for Biomedical Research of Kaunas University of Medicine  
Eiveniu str. 4, LT-50009 Kaunas, Lithuania*

<sup>2</sup>*Department of Applied Electronics, Kaunas University of Technology  
Studentų str. 50-327, LT-3031 Kaunas, Lithuania*

<sup>3</sup>*Institute of Biomedical Engineering, Kaunas University of Technology  
Studentu str. 65-104, LT-51369 Kaunas, Lithuania*

### Abstract

Development of techniques for evaluation of the tissues structure is one of the main tasks in medical diagnostics. At present time the ultrasound imaging technique is widely used for qualitative evaluation of tissue structure. Tissue evaluation methods are using A, B, M scans of tissues. Significant part of valuable information is lost by using common diagnostic methods. New technique for tumours tissue structure evaluation using ultrasound radiofrequency signals (RF) is presented in this paper. Echospectral methods allow get additional information about tissue structure, gives more information about treatment process. The mean spectral frequency, the width of power spectrum and effective value of correlation function are used for tumours tissue characterization during brachytherapy treatment.

**Keywords:** ultrasound, intraocular tumours, signal processing

### Introduction

Ultrasound is the most informative examination method of the eye, because common optical examination methods carry less diagnostic information. Evaluation of anterior eye segment depth, angle configuration, lens position, differentiation of iris, cysts of the eye elements and tumours, and their geometrical and structural parameters is possible using ultrasound examination.

Differential diagnostic of eye tumours is one of the main problems in ophthalmology. Eye tumours, especially melanoma, are very dangerous because of metastasis to other organs. Intraoculars tumours – wide spectrum of benign and malignant pathology – the reason of sight or life lost [2]. Early detection of this pathology and the right diagnosis is crucial for proper treatment and prognosis. It is possible biopsy of intraocular tumours but the safety and reliability of biopsy technique is doubtful. One of most reliable methods for detection of eye tumours is ultrasound [3, 4, 5]. The main indicators for differentiation of intraocular tumours – geometry, size, shape – are mostly used in clinical practice, also it is important blood circulatory, biochemical indicators and other additional information. It is the main parameters for clinical decision: in making diagnosis, prognostication and choosing the right treatment tactics [7, 8]. Set of investigations is made on ultrasonic characterization of eye tissues [1, 4, 6, 9, 10]. Advanced ultrasound image and signals processing methods are used in order to extract valuable information of tumours structure and features [1, 4, 5].

An effective radiation method – brachytherapy - is applied for melanoma treatment with a purpose to kill cells

of intraocular tumours. The application of this method in Eye Clinic of Kaunas University of Medicine started in 2005. A radioactive metal plate (cobalt 60, ruthenium 106, iodine 125, palladium 103) is placed into outer side of the eye sclera, covering the tumour. It is left in the eye till required radiation dose is given, 5-7 days, afterwards it is removed. After removing the plate, a scarring tissue developing in the place of melanoma if treatment is positive. Using ultrasound investigation it is important to evaluate changes of tumour capacity – it should decline, scarring process, ultrasound volume before and after brachytherapy. The changes of tumours parameters – tumour base size, height, position, concentration of tumour material – are mostly evaluated using ultrasound investigation before and after brachytherapy [11, 12, 13, 14]. One of the newest method of evaluation of tumours structure changes before and after brachytherapy is processing of ultrasound radiofrequency (RF) signals for assessing a tumour structure, the scarring process and the effectiveness of brachytherapy.

### Methods of investigation

Ultrasound B-scan image carries information for determination of tumours shape, topography, tumour pervasion into the eye fundus (Fig.1).

Eye tumour size, shape, present of retina detachment, vascular excavation are determined from the B-scan image. However there is not enough information for evaluation of the tumour tissue microstructure. Therefore it was investigated application of RF signals captured from the eye tumour, which carry a valuable information of a tissue structure. The signal amplitude depends on the values of

acoustic impedances and tissue density, hence RF signal supplies a valuable information of a tissue morphology – shape, homogeneity and structure.

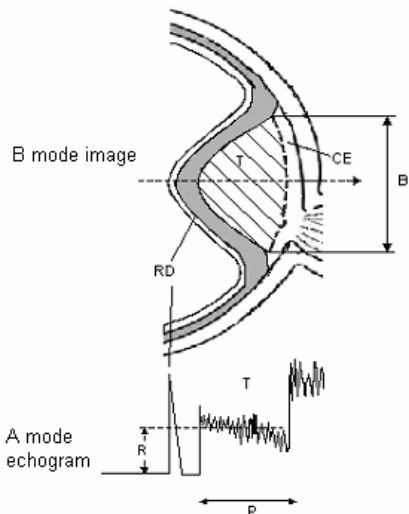


Fig. 1. B - view of eye tumour (above), A - echogram (below), T – tumour, RD – retinal detachment, CE – choroidal excavation, P- height of tumour, R – mean amplitude of reflected signal, B – base of tumour

The main aims of this research work were to create methodic for ultrasound RF signals capture from intraocular tumours before and after brachytherapy and to analyze spectral signal processing method for differential eye tumour structure diagnosis.

Main objectives of evaluation of tumours structure are:

- a) tumours differentiation;
- b) evaluation of changes of brachytherapy treatment;
- c) creation of database and clinical decision support system.

An informative and correct original data of ultrasound investigations have been used for realization of above mentioned objectives which were acquired according to the developed methodic.

Patients have been examined with the ultrasonic diagnostic imaging system Mentor Advent, using A/B scan mode with the 7 MHz frequency transducer for A-scan ultrasound signal and 12,5 MHz B-scan ultrasound image acquisition. The block diagram of the developed computerized ultrasound system for intraocular tumour image and signals acquisition and analysis is shown in Fig.2.

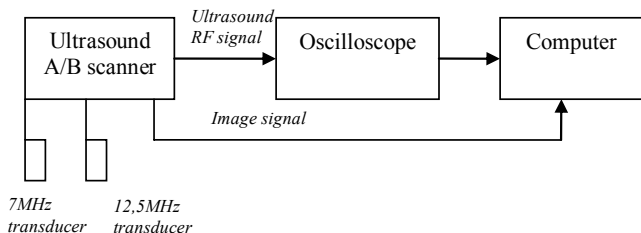


Fig. 2. Block diagram of the developed computerized ultrasound system for image and signals acquisition and analysis

Investigations based on the Echo - Spectral Method for Tissue Evaluation were made. The mentioned method was simply modified. The properties of echo signals were changed using the windows method for digital signal processing. Rectangular, Hamming, Blackmann and Gaus windows were applied.

The signals obtained from diagnostic intraocular tumours scanning are the object of this investigation. Assuming that the analyzed system is linear, the echo signal can be described as:

$$U(t) = h(t) * a(t) = \int h(x) \cdot a(t - x) dx; \quad (1)$$

where  $h(t)$  is the tissue time response,  $a(t)$  is the waveform of the transmitted impulse,  $t$  is the time.

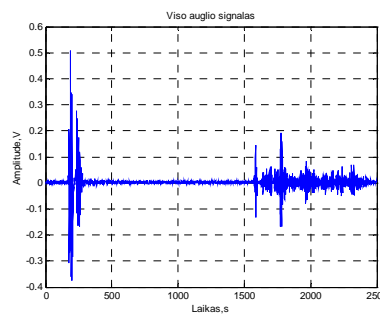


Fig. 3. Echo signal obtained by scanning intraocular tumour before brachytherapy

The amplitude of a radio frequency echo signal distribution equals to the sum of the signals from each reflecting point in the radiation line:

$$U(n) = \sum_{m=0}^{M-1} g_n(t_m) \cdot \delta(Z - Z_n); \quad (2)$$

there  $g_n$  is the echo signal from each reflecting point  $Z_n$ ;  $n = 1, 2, \dots, N$ ;  $N$  – number of reflecting points,  $t_m = \Delta t m$ ;  $M$  – number of frames of transmitted signal,  $\delta(Z - Z_n)$  - delta function.

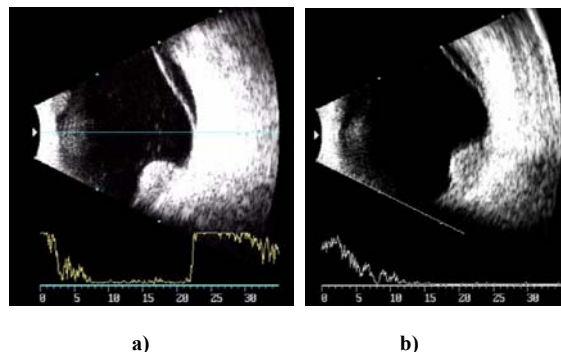


Fig. 4. B-scan image of tumour ultrasonic investigations before (a) and after (b) brachytherapy

Power spectrum of the echo signal is calculated using the discrete Fourier transformation. The power spectrums obtained from a tumour before and after brachytherapy are

different. This difference can be evaluated by the value of the power spectrum width:

$$\Delta f = f_{max} - f_{min}; \quad (3)$$

There  $f_{max}$  is the maximal frequency of the power spectrum, calculated by (4) equation,  $f_{min}$  is the minimal frequency of the power spectrum, calculated by Eq.5. Equations for calculation of the maximal and minimal frequencies are the following:

$$\int_0^{f_{max}} S(f) \cdot df = 0,95 \cdot \int_0^{\infty} S(f) \cdot df; \quad (4)$$

$$\int_0^{f_{min}} S(f) \cdot df = 0,05 \cdot \int_0^{\infty} S(f) \cdot df; \quad (5)$$

where  $S(f)$  is the power value of the frequency  $f$  in a echo signal power spectrum:

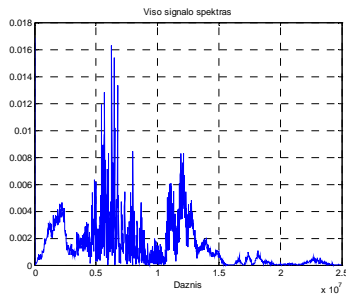


Fig. 5. Distribution of power spectrum of the signal obtained from scanning intraocular tumour before brachytherapy

Autocorrelation function of an echo signal also can give information about the microstructure of a tissue, its influence to the echo signal behavior and other valuable information contained in a radio frequency signal. The autocorrelation function is calculated by correlation of the echo signal with the same shifted signal. Distribution of the autocorrelation function depends on the investigated tissue type. The effective value of the autocorrelation function was calculated to evaluate tumour's tissue.

The objectives of this work were:

- to investigate possibilities to use echo signals for tumours tissue characterization;
- to find new parameters for qualitative evaluation of tissue microstructure;
- to establish the values of parameters to define progress of treatment.

### Results of experimental investigations

The data base of echo signals obtained by diagnostic examination of eye tumour with ultrasound was created. The data base consists of 15 pairs of echo signals from tumour investigation before and after brachytherapy treatment.

Experimental investigation of echo signals from tumour before and after brachytherapy was accomplished. The aim of this investigation was to define the possibilities to evaluate different structures of tissues qualitatively and quantitatively. The behavior of echo spectral characteristics of radio signals

by using different windows (Rectangular, Hamming, Blackmann and Gaus windows) for echo signal processing was investigated. It is difficult, or beside the purpose, to use signal “from the whole eye” for the echo signals quantitative definition. The windows from the echo signals (from the beginning, middle and the end of signal) were extracted for subsequent processing. The power spectrum for all these windows was calculated and the results of calculation for different cases (signals obtained from tumours before and after brachytherapy) were compared.

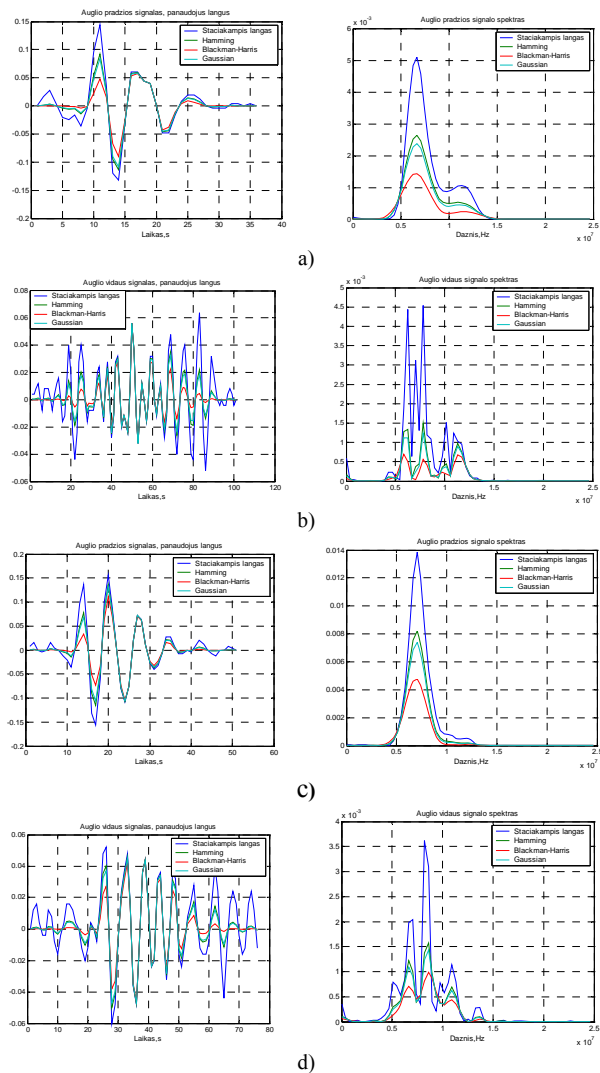


Fig. 6. The radio signals and their power spectrum: a) and c) extracted from beginning, b) and d) extracted from the middle, there a) and b) – signals from tumour before the brachytherapy, c) and d) – signals from tumour after brachytherapy

Echo signals were corrected using the “windows method”. This method allows “to improve signals quality,” before the processing, to remove noise frames from the signal power spectrum. The “windows method” influence to signal quality using rectangular, Hamming, Blackmann and Gaus windows was investigated. After analysis of investigation results was established, that using of the

Hamming window gives the best results evaluating echo spectral characteristics of radio signals.

Investigation results has shown that reliable difference exists between the values of a power spectrum and autocorrelation function processing signals from tumours before and after brachytherapy. The value of the mean frequency in the case “before the brachytherapy” is bigger. The investigation results (Table 1) has shown that the effective value of the correlation function also can be used for tumours “before and after brachytherapy” characterization.

Table 1. Distribution of power spectrum mean values and effective values of correlation function

Parameter- Investig. object	Power spectrum		Effective value of correlation function	
	Mean value, MHz	STD, MHz	Mean value	STD
Tumours before BCHT	6,52	±1,95	0,324	±0,037
Tumours after BCHT	4,93	±1,98	0,415	±0,044
Tumours before BCHT, (using windows method)	6,81	±1,37	0,394	±0,023
Augliai po BCHT naudojant langų metodą	5,12	±1,01	0,488	±0,027

Visible differences in a power spectrum can be established investigating signals from tumours before and after brachytherapy. The signals from tumours after brachytherapy became cleaner, slopes the noise components in a power spectrum narrows the power spectrum width, decrease all components of the power spectrum. We can state that this is related to changes in tumours tissue structure. The proposed in this work parameters (mean frequency, the width of a power spectrum and effective value of the correlation function) may be used tracking treatment process, solving problems related with tissues characterization and identification.

#### Reference

1. Žakauskas M., Mačiulis A., Kopustinskas A., Paunksnis A., Kurapkienė S., Jegelevičius D. Echospėktriniai audinių įvertinimo metodai. Elektronika ir elektrotechnika. ISSN 1392-9631. 2004. Vol.7(56). P. 70-73.

2. Collaborative ocular melanoma study group. Comparison of clinical, echographic, and histopathological measurements from eyes with medium sized choroidal melanoma in the collaborative ocular melanoma study. COMS report No.21. Arch Ophthalmol. 2003. Vol.121(8). P.1163-1171.
3. Frazier Byrne S., Green R. L. Ultrasound of the eye and orbit. 1992.
4. Jegelevičius D., Lukoševičius A., Paunksnis A., Šebeliauskienė D. Parameterisation of ultrasonic echographic images for intraocular tumour differentiation. Ultragarasas. 2002. No.1(42). P.50-55.
5. Paunksnis A., Lukoševičius A. High resolution ultrasonic investigations of the eye tissue pathological changes. In abstracts of 9th International Congress of Eye Research, Helsinki. 1990. P.122.
6. Romijn R. L., Thijsen J. M., Oosterveld B. J., Verbeek A. M. Ultrasonic differentiation of intraocular melanomas: parameters and estimation methods. Ultrasonic imaging. 1991. Vol.13(1). P.27-55.
7. Jegelevičius D., Lukoševičius A., Paunksnis A., Barzdžiukas V. Application of data mining technique for diagnosis of posterior uveal malnoma. Informatica. 2002. Vol.13(4). P. 455-464.
8. Paunksnis A., Šebeliauskienė D., Mačiulis A., Kopustinskas A. Echografinio vidinių akies auglių ir tinklainės degeneracijų pokyčių klasifikavimo analizė. Elektronika ir elektrotechnika. 2002. No.5(40). P.76-80.
9. Šebeliauskienė D., Paunksnis A. Echographic differentiation of malignant intraocular tumours. Ultragarasas. 2001. No.4(41). P.25-28.
10. Verbeek M., Thijsen J. M., Cuypers M. H. Echographic differentiation of intraocular tumours. Acta Ophthalmologica. 1994. Vol.72. P.416-422.
11. Coleman D. J., Silverman R. H., Rondeau M. J., Coleman J. A., Rosberger D., Ellsworth R. M., Lizzi F. L. Ultrasonic tissue characterization of uveal melanoma and prediction of patient survival after enucleation and brachytherapy. Am. J. Ophthalmol. 1991. Vol.112(6). P. 682-8.
12. Novak-Andrejčic K., Jancar B., Hawlina M. Echographic follow-up of malignant melanoma of the choroid after brachytherapy with 106Ru. Klin Monasbl Augenheilkd. 2003. Vol.220(12). P.853-60.
13. Kaiserman I., Anteby I., Chowers I., Blumenthal E. Z., Kliers I., Pe'er J. Changes in ultrasound findings in posterior uveal melanoma after Ruthenium 106 brachytherapy. Ophthalmology. 2002. Vol.109(6). P.1137-41.
14. Torres V. L., Allemann N., Erwenne C. M. Ultrasound biomicroscopy features of iris and ciliary body melanomas before and after brachytherapy. Ophthalmic Surg. Lasers Imagin. 2005. Vol.36(2). P.129-38.

A. Paunksnis, S. Kurapkienė, A. Mačiulis, A. Lukoševičius, M. Špečkauskas

#### Echospėktrinio audinių įvertinimo metodo taikymas brachiterapinio gydymo eigai įvertinti

##### Reziumė

Svarbus medicininės diagnostikos uždavinys yra audinių struktūros ir morfologijos įvertinimas, klasifikavimo parametų paieška, signalų apdorojimo metodų taikymas audinių struktūros analizei. Labiausiai paplitęs kokybinės audinių analizės ir vizualizacijos metodas - ultragarasinė vizualizacija. Čia naudojami ultragarasinių skenerių A, B ir M režimai. Tačiau taikant įprastus metodus prarandama dalis aidi slypinčios vertingos informacijos. Echospėktriniai metodai leidžia veiksmingiau naudoti informaciją, esančią radijo dažnio aidi. Straipsnyje aprašomos ultragarasinių radijo dažnių signalų panaudojimo, taip pat naujų echospėktrinių parametų panaudojimo brachiterapinio gydymo eigai įvertinti galimybės.

Pateikta spaudai 2007 10 02

DOI: 10.5755/j01.u.62.4.17045