

Progress towards noninvasive intraocular tumor diagnostics

V. Puzienė¹, D. Jegelevičius¹, A. Lukoševičius¹, R. Jurkonis¹, A. Paunksnis², V. Barzdžiukas²

¹Biomedical Engineering Institute of Kaunas University of Technology,
Studentu str. 65, LT-51369 Kaunas, Lithuania, E-mail.: viktorija.puziene@gmail.com

²Department of ophthalmology, Institute for Biomedical Research of Kaunas University of Medicine
Eivenių str. 4, LT-50009 Kaunas, Lithuania

Abstract

Differential diagnosis of human eye tumors is one of the most important problems in ophthalmology in dealing with cancer prevention and diagnostics. Noninvasive diagnostics methods are of a high importance managing eye tumors. The main directions are: ultrasound and optical methods. State of the art of these methods shows trends for a further development.

Keywords: ophthalmic tumor, noninvasive diagnostics, medical ultrasound, optical methods.

Introduction

Intraocular tumors have a wide spectrum of benign and malignant pathology and often are the reason of sight or life lost [1]. Early detection of this pathology and the right diagnosis is crucial for proper treatment and prognosis. Differential diagnosis of human eye tumors is one of the most important problems in ophthalmology in dealing with cancer prevention and diagnostics [2]. The main indicators for differentiation of intraocular tumors are their geometry, size, shape, color; blood circulatory, biochemical indicators and other additional information also is important [3]. These are the main parameters for clinical decision in making diagnosis, prognosis and choosing the right treatment tactics.

Noninvasive diagnostics methods are of a high importance managing eye tumors. The main noninvasive diagnostic methods of eye tumors are optical and ultrasound methods. Also other imaging modalities like computed tomography (CT), magnetic resonance imaging (MRI), positron emission tomography (PET) are used in some special cases [3]. Diagnostic methods can be compared by penetration and resolution as is presented in Fig. 1.

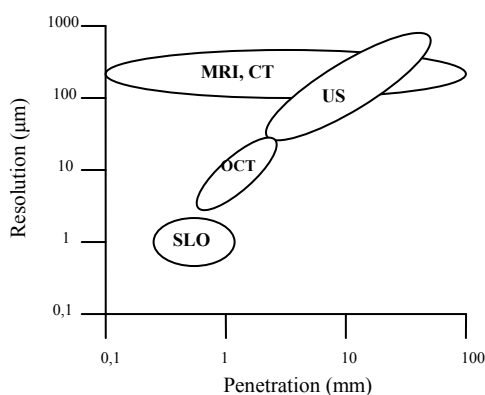


Fig. 1. Optical coherence tomography (OCT), scanning laser ophthalmology (SLO), magnetic resonance imaging (MRI) and computer tomography (CT) compared to ultrasound (US) regarding resolution and penetration

The aim of the present paper is to give an overview of noninvasive optical and ultrasound methods that are used to characterize eye tumors.

Optical methods for noninvasive ophthalmic tumor characterization

Optical methods are based on the optical imaging of an eye using either visible light (ophthalmoscopy, autofluorescence, angiography) or coherent infrared light (optical coherence tomography (OCT), scanning laser ophthalmology (SLO)).

Fundus photography (ophthalmoscopy)

Optical images of intraocular tumors (Fig. 2) are of a high importance and usually are taken by a fundus camera or a portable ophthalmoscope or just viewed by a physician using lens. This imaging modality in most cases is the first in diagnosing an eye tumor. An eye fundus image is used for documentation of initial tumor characteristics: pigmentation, basal dimensions, proximity to ocular structures, retinal detachment and other associated features [3]. Changes of the tumor over the time are also very important in diagnostics and also in evaluation of response to therapy.

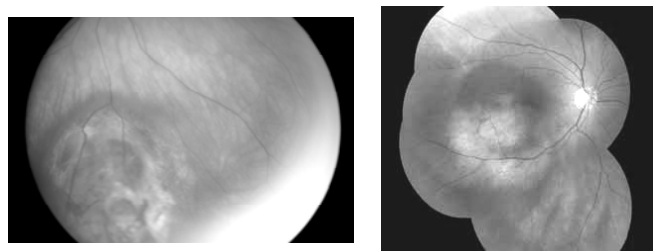


Fig. 2. Intraocular tumors in eye fundus photographs (right – montage image of five fundus images)

The main drawbacks of this diagnostic method are: invisibility of an internal structure of a tumor; the limited field of a view. More recent improvements in a technology include a wider angle and nonmydriatic cameras and software that allow digital images to be adjusted for illumination, contrast, and other enhancements and to be

assembled into montage images that simulate panoramic fundus photographs.

Ocular angiography

Two major forms of ocular angiography are used in intraocular tumors diagnostics: fluorescein angiography (FA) and indocyanine green angiography (ICG) [4]. However these modalities are used only as ancillary tests in specific circumstances. Additional blood vessels of a tumor are seen using these methods. New technologies allow to use a high speed videoangiography which diagnostic value is yet to be proved.

Optical coherent tomography (OCT)

OCT is a technique that generates a high-resolution image using light (usually infrared). The image is formed from the light reflected and transmitted from the tissue of interest, analogous to ultrasound waves used in ultrasonography [5].

The main limitation of OCT in ocular oncology is its limited depth of penetration. OCT can be helpful for the evaluation and identification of alterations of tumors and tumor-like lesions of retina and retinal pigment epithelium. Also OCT can be used for imaging of anterior segment tumors: iris and ciliary body.

Autofluorescence

Autofluorescent fundus photography uses advantage of the stimulated emission (using imaging wavelength in a range 475-515 nm) of light from naturally occurring fluorophores within the eye [6]. Autofluorescence can be evaluated using a common fundus camera or (produces better quality imaging) confocal scanning laser ophthalmoscope (SLO). Recent studies suggest that autofluorescence may be helpful in the evaluation of choroidal melanocytic tumors. Features associated with more benign tumors show reduced autofluorescence and features associated with high risk tumors demonstrate increased autofluorescence.

Ultrasound methods for noninvasive ophthalmic tumor characterization

Ophthalmic ultrasonography is one of the most important tools for diagnostic evaluation of intraocular tumors [3]. Ultrasonography data obtained from intraocular tumors can be processed in two different levels: on level of ultrasound image and on level of ultrasound signal (not detected radiofrequency (RF) signal). Also in both cases signal/image processing can be done using two approaches: model based (with consideration of ultrasound and tissue properties and models) and blind statistical properties of the signals. In next sections research articles are discussed in such classified context. Experience of some other tumor localizations inspected by US can be considered as useful for eye tumor investigation progress too.

Image processing based methods

Image processing based methods are built on detected ultrasound RF signals. These detected signals with the help of scan conversion algorithms forms two dimensional

images what are displayed in a grey scale. B-scan is usually obtained with a 10-15 MHz probe.

B-scan ultrasonography generates 2-D image which is used in a clinics routine to evaluate the overall tumor shape of scanning section, precise basal dimensions (height, cross-sectional areas and volume of the intraocular tumors), choroidal excavation, extrascleral tumor extension, as well as retinal detachment, vitreous and subretinal hemorrhage, etc. Decision support algorithm (based on decision trees) for the differential diagnosis of intraocular tumors using parameters described above allows to differentiate tumors from other tumor-like formations [7].

Quantitative statistical texture parameters of digital ultrasound B-scan images were investigated in [8]. There were suggested quantitative image parameters of tumor image texture, i.e. statistical quantities of co-occurrence matrices: energy, entropy, contrast, homogeneity and correlation. Preliminary analysis of co-occurrence matrixes for different tumor kinds have shown that texture statistics of different kind melanomas differs significantly. The lack of validation on a big enough database does not allow to conclude that this approach has a diagnostic value.

High-frequency (from 30 MHz) ultrasound imaging (HFUI or ultrasound biomicroscopy (UBM)) is useful in detecting, diagnosing and evaluating anterior eye segment tumors. This method plays an important role as a complementary diagnostic method for anterior uveal melanomas, also allows to help in planning brachytherapy or surgery and follow-up after treatment [9, 10]. UBM clearly characterizes the tumor as a medium echoic solid mass with acoustic hollowing. In article [9] is stated that "these changes of eye tissue could not be illustrated by other imaging systems, such as MRI or slit-lamp examination".

The paper [11] investigates computational approach to thyroid tissue characterization in ultrasound images. It is based on the hypothesis that tissues in thyroid ultrasound images may be differentiated by directionality patterns. These patterns may not be always distinguishable by the human eye because of the dominant image noise. The encoding of the directional patterns in the thyroid ultrasound images is realized by means of the Radon Transform features. A representative set of ultrasound images, acquired from 66 patients was constructed to perform experiments that test the validity of the initial hypothesis. Authors conclusion was that supervised classification experiments showed that the proposed approach is capable of discriminating normal and nodular thyroid tissues, whereas nodular tissues can be further characterized as of high or low malignancy risk. This method can be considerable in investigation of eye tumors.

Signal processing based methods

Ultrasound RF signals processing based methods found in literature can be classified to A-scan based and B-scan based methods. The main direction of signal analysis is spectral analysis [2, 12 – 16].

The standardized A-scan ultrasonography (calibrated to tissue sensitivity) shows tumor thickness, internal reflectivity, spontaneous vascular pulsations [3] and in a clinical practice is evaluated using detected US RF

envelope. Uveal melanomas usually are indicated by low to medium internal reflectivity and lesions such as metastasis and hemangiomas in many cases show higher internal reflectivity [3].

Tumors tissue structure evaluation using A-scan ultrasound radiofrequency signals (RF) is presented in [2]. Information about the tissue structure and treatment process has been obtained using echospectral methods. Three parameters are used for a tumors tissue characterization during a brachytherapy treatment: the mean spectral frequency, the width of power spectrum and effective value of the correlation function. Authors' state that the signals from tumors after brachytherapy become cleaner, slopes the noise components in a power spectrum, narrows the power spectrum width, decrease all components of the power spectrum due to changes in a tumors tissue structure [2].

The goal of the study [12] was to differentiate histological subtypes of a malignant melanoma using wave spectral analysis in 8 enucleated eyes. An broadband focused transducer with a frequency range of 7-12 MHz and a center frequency of 10 MHz was used. Maximum size of the scatterer and the root mean square velocity fluctuation were obtained from the backscattering coefficient using a digital model. The attenuation coefficient over frequency was estimated also. The results show a significant increase in the attenuation coefficient and the backscattering coefficient in spindle cell type of malignant melanoma in comparison to the mixed cell type. Spindle cells have uniform and compact histological pattern which contributes to an increase in a scatterer size and the root mean square velocity fluctuation.

B-scan based US images are used for the delineation of a tumor region and then US RF signal of this region is extracted and analyzed [13].

Ultrasound backscatter analysis can detect extravascular matrix patterns (EMP) [13]. EMP in histological sections of uveal melanoma is an independent indicator of a metastatic risk. Digitized 10 MHz RF ultrasound data of tumor region were processed to generate parameter images representing the size and concentration of ultrasound scatterers [13]. The following acoustic parameters were considered: ultrasound scatterer concentration in the posterior aspect of tumor, the percentage of posterior low-concentration scatterers, the percentage of anterior small to medium-sized scatterers, core region scatterer concentration standard deviation, the variance of the vertical orientation at detailed level. Parameters images are calculated using the normalized power spectra in 0.5x0.5 mm analysis regions. The power spectra were analyzed using a linear least-squares fit which provided values of the spectral slope (dB/MHz) and intercept (dB). These parameters provide measures of amplitude dependence of frequency (slope) and amplitude independent of frequency (intercept). These spectral parameters are fitted into a mathematical model of an acoustic backscatter by stochastic distributions of scatterers and are used to estimate the effective scatterer diameter and the acoustic concentration. By the use of a support vector machine classifier 93.1% of cases were correctly classified based on histological findings.

Studies of [14] investigated if melanomas grouped on the basis of microvascular patterns are separable by the ultrasound spectrum analysis. There were scanned 40 melanomas in the investigation using a 10 MHz ultrasound unit equipped for digitization of radio frequency data. Acoustic spectral parameters were related to the scatterer size and concentration and were compared between 14 melanomas with a nevuslike microcirculation and 26 with foci of high-risk microvascular structures. It was shown that smaller scatterer size, lower acoustic concentration and greater spatial variability correlate with high-risk microvascular patterns. Authors [14] conclude that nonvascular extracellular matrix components associated with microvessels may be responsible for the correlation of acoustic parameters with microvascular pattern and distribution.

Three-dimensional high-frequency characterization of cancerous tissue of lymph was investigated using backscattered echo signals of 25.6 MHz ultrasound [15]. The ultrasound signals were processed using 3-D cylindrical regions of interest to yield four quantitative ultrasound estimates based on power spectra and associated with tissue microstructure: effective scatterer size, acoustic concentration, intercept and slope. Quantitative ultrasound estimates are computed following the established methods using two scattering models (straight line and Gaussian). The results show that metastatic tissues can be differentiated from cancer-free tissues using the slope or the scatterer-size estimates. It is indicated that metastatic tissues have the average effective scatterer size significantly larger than that in cancer-free tissues.

In article [16] authors conclude: melanomas exhibit the smallest scatterer sizes and thought to be related with small vessels and aggregations of specialized cells – melanocytes; metastatic carcinomas exhibit larger scatterer sizes associated with aggregations of cells within the tumor stroma; hemangiomas exhibit large scatterer sizes associated with internal blood filled cavities. Acoustic concentration and scatterers size estimates by themselves alone could not allow reliable classification of tumors.

Cancer tissue modeling

In this section we try to review modeling approach, when models of tumors are developed in animals or in-vitro [17-20]. These models of cancer tissue are pre-defined or known structure therefore ultrasonography data processing could be directed in an optimized manner for searching specific patterns in images or features of signals.

The report [18] describes research results for spectral comparisons of four classes of human intraocular tumors and four classes of implanted tumors in the athymic nude mouse. Radiofrequency scan data were converted to digital form and investigated in the frequency domain from 5 to 15 MHz. Three parameters of the power spectrum [18] have found to be collectively more significant for tumor characterization: spectral slope, intercept and statistical standard error at the intercept, or simply residual. Characteristics of the normalized power spectra were found to be completely different among human spindle cell malignant melanomas, mixed/epithelioid malignant melanomas, metastatic carcinomas, and hemangiomas.

Comparing spectral properties of human intraocular and implanted tumors it was shown that human spindle cell malignant melanomas and implanted melanomas exhibit similar characteristics. Human intraocular metastatic tumors from the lung were found to exhibit characteristics similar to those of implanted lung tumors. Researchers conclude that these results indicate that the implantation of human tumor cell lines in the nude mouse may provide a very useful model for application of diagnostic and therapeutic ultrasound modalities to human intraocular tumors.

The paper [19] studies imaging of a tissue-specific ultrasound attenuation. The imaged parameter is the mean attenuation coefficient between the probe and the given pixel position. The analyzed method is based on the least-mean-squares approximation of short segments of A-scan radio-frequency signals using a physical model. Some of the tissue structures are shown by a parametric image. Testing of the method is done on images of a tissue-mimicking phantom and on clinical images of liver and thigh showed relatively good agreement of the estimated attenuation coefficients with the known reference values. Authors conclude that the method of parametric imaging has the potential to give valuable information for assessing

attenuation properties of tissues and possibly for improving the spatial resolution.

Three-dimensional (3D) tissue models can improve ultrasonic tissue characterization [20]. Potential applications of ultrasound for tumor diagnosis are limited by the reason that anatomic sites in tissue responsible for ultrasonic scattering are unknown. Precise 3D models of tumor tissues can help identify the scattering sites. For this reason three mammary tumors were investigated: a rat fibroadenoma, a mouse carcinoma, and a mouse sarcoma. A 3D acoustic tissue model, termed 3D impedance map (3DZM), was carefully constructed from consecutive histologic sections for each tumor [20]. Spectral estimates such as the scatterer size and the acoustic concentration were obtained from the 3DZMs and compared to the same estimates obtained with ultrasound. Scatterer size estimates for three tumors were found to be similar (within 10%). The 3DZMs were also used to extract tissue-specific scattering models. The scattering models were found to allow clear distinction between the three tumors. This distinction demonstrated that ultrasonic tissue characterization techniques might be helpful for noninvasive clinical tumor diagnosis. This method can be fitted for eye tumors.

Table 1. Ultrasound methods and parameters used for diagnostics of intraocular tumors

	Method	Parameters	Literature reference
US image processing based	B-scan (conventional and high frequency)	Geometrical parameters (height and cross-sectional areas), microstructure, shape, reflection intensity	[7], [9], [10]
		Statistical texture parameters	[8], [11]
US signal processing based	A-scan ultrasonography	Tumor thickness, internal reflectivity, spontaneous vascular pulsations	[3], [17]
		Mean spectral frequency, the width of power spectrum, effective value of correlation function, parameters from backscattering coefficient, attenuation coefficient	[2], [12], [19]
	B-scan (conventional and high frequency)	Acoustic spectral parameters (scatterer size, acoustic concentration, spatial variability); backscattering coefficient, attenuation coefficient, and root mean square velocity fluctuation; spectral slope, intercept, statistical standard error at the intercept	[13], [14], [18]
	3D high-frequency characterization	Effective scatterer size, acoustic concentration, intercept and slope of 3-D cylindrical regions of interest calculated from spectral parameters	[15], [20]

Discussion

Ultrasound seems to be one of the most informative examination methods of the eye, because common optical examination methods carry less diagnostic information or their penetration depth is too small. In some cases optical instruments not assure imaging of eye bottom due to opacity of anterior eye chamber and lens. On the other hand optical instruments are more widely available for ophthalmologists than ultrasonography instruments, which are concentrated only at highest level centers. Simple optical instruments are being used on the primary level screening and diagnostics instruments – on the secondary.

Ultrasound deals with image processing based methods and signal processing based methods using statistical processing or physical model based methods. US echography has excellent features: non invasiveness, high

resolution, and informativity and it can give very important geometrical and also structural parameters of tumor. Ultrasound methods and parameters used for an eye tumor characterization reviewed here are summarized in Table 1. A scans (one dimensional detected or radiofrequency signals) and B scans (two dimension images) are used for tumor characterization, but radiofrequency ultrasonic signal has a more significant information to compare with detected signals or B-image. Ultrasound RF signals processing improves characterization possibilities of the tumors.

Combination of optical and ultrasonic methods would be the best for diagnosing eye tumors because of carrying versatile information about the tissue of tumor. Information obtained from optical and ultrasound waves passing the same tissues could be complementary.

Acknowledgment

This work was partially sponsored by the Agency for Science, Innovation and Technology under the Eurostars project E! 4297 NICDIT "A Non-Invasive Expert System for Diagnosis of Intraocular Tumors".

References

- Collaborative ocular melanoma study group.** Comparison of clinical, echographic, and histopathological measurements from eyes with medium sized choroidal melanoma in the collaborative ocular melanoma study. COMS report No.21. Arch Ophthalmol. 2003. Vol.121(8). P.1163-1171.
- Paunksnis A., Kurapkienė S., Mačiulis A., Lukoševičius A., Špečkauskas M.,** The use of echospectral methods of tissue evaluation for follow-up of brachytherapy treatment. Ultrasound. No.4(62). 2007. P.45-48.
- Harbour J. W., Correa Z. MS, MD, PhD.** Pearls for imaging and diagnosis in ocular oncology. Retina today, July/August 2009. P. 61-65.
- Picolino F. C., Borgia L., Zinicola E.** Indocyanine green angiography of circumscribed choroidal hemangiomas. Retina. 1996. Vol.16(1). P.19-28.
- Sensen Ch. W., Hallgrímsson B. (editors).** Advanced imaging in biology and medicine. Springer-Verlag. 2009.
- Schmitz-Valckenberg S., Holz F. G., Bird A. C., Spaide R. F.** Fundus autofluorescence imaging: review and perspectives. Retina. 2008. Vol.28(3). P.385-409.
- Jegelevičius D., Lukoševičius A., Paunksnis A., Barzdžiukas V.** Application of data mining technique for diagnosis of posterior uveal melanoma. Informatica. Institute of Mathematics and Informatics, Vilnius. 2002. Vol. 13. No. 4. P.455-464.
- Jegelevičius D., Lukoševičius A., Paunksnis A., Šebeliauskienė D.,** Parameterisation of ultrasonic echographic images for intraocular tumour differentiation. Ultrasound. 2002. No.1(42). P.50-56.
- Kawana K., Okamoto F., Nose H., Oshika T.,** Ultrasound biomicroscopic findings of ciliary body malignant melanoma, Jpn J Ophthalmol. Jul-Aug. 2004. Vol.48(4). P.412-414.
- Torres V. L., Allemann N., Erwenne C. M.** Ultrasound biomicroscopy features of iris and ciliary body melanomas before and after brachytherapy. Ophthalmic Surg Lasers Imaging. Mar-Apr. 2005. Vol. 36(2). P.129-138.
- Savelonas M. A., Iakovidis D. K., Dimitropoulos N., Maroulis D.** Computational characterization of thyroid tissue in the radon domain. Proc. of the 12th IEEE International Symposium on Computer-Based Medical Systems. 2007. P. 189-192.
- Sujana J. S., Suresh S. H., Swarnamani S., Biswas J., Gopal L.** Ultrasonic characterisation of malignant melanoma of choroid. Indian J Ophthalmol. 1998. Vol.46. P.153-157.
- Coleman D. J., Silverman R. H., Rondeau M. J., Boldt C. H., Lloyd O. H., Lizzi F. L., Weingeist T. A., Chen X., Vangveeravong S. and Folberg R.** Noninvasive in vivo detection of prognostic indicators for high-risk uveal melanoma. Ultrasound parameter imaging. Ophthalmology. March 2004. Vol.111. Issue 3. P. 558-564.
- Silverman R. H., Folberg R., Boldt H. C., Llod H. O., Rondeau M. J., Mehaffey M. G., Lizzi F. L., Coleman D. J.** Correlation of ultrasound parameter imaging with microcirculatory patterns in uveal melanomas. Ultrasound in medicine & biology. 1997. Vol. 23. No.4. P. 573-581.
- Mamou J., Coron A., Hata M., Machi J., Yanagihara E., Laugier P., Feleppa E. J.** Three-dimensional high-frequency characterization of cancerous lymph nodes. Ultrasound in Med.& Biol. 2010. Vol. 36. No.3. P. 361-375.
- Lizzi F. L., Feleppa E. J., Alam S. K. and Deng C. X.** Ultrasonic spectrum analysis for tissue evaluation. Pattern Recognition Letters. February 2003. Vol. 24. No. 4. P. 637-658(22).
- Blanco P. L., Marshall J. C. A., Antecká E., Callejo S. A., Souza F. J. P., Saraiva V. and Burnier M. N.** Characterization of ocular and metastatic uveal melanoma in an animal model. Investigative Ophthalmology & Visual Science, December 2005. Vol. 46. No. 12. P. 4376-4382.
- Coleman D. J., Lizzi F. L., Silvermon W. H., Helson L., Torpey J. H. and Rondeau M. J.** A model for acoustic characterization of intraocular tumors. Invest Ophthalmol. 1985. Vis Sci 26. P.545-550.
- Jirik R., Taxt T., Jan J.** Ultrasound attenuation imaging. Journal of Electrical Engineering. 2004. Vol. 55. No. 7-8. P. 180-187.
- Mamou J. M.,** Ultrasonic characterization of three animal mammary tumors from three-dimensional acoustic tissue models., Ph.D. thesis. University of Illinois at Urbana-Champaign, 2005.

V. Puzienė, D. Jegelevičius, A. Lukoševičius, R. Jurkonis, A. Paunksnis, V. Barzdžiukas

Neinvazinės vidinių akies auglių diagnostikos pažanga

Reziumė

Diferencinis žmogaus akių navikų charakterizavimas yra viena iš svarbių problemų oftalmologijoje sprendžiant su vėžio profilaktika ir diagnostika susijusius klausimus. Akių navikų tyrimui didžiulę reikšmę turi neinvaziniai diagnostikos ir vizualizavimo metodai. Pagrindinės šių metodų kryptys yra optiniai ir ultragarsiniai metodai. Jų raida rodo šios srities tobulinimo tendencijas.

Pateikta spaudai 2010 06 16

DOI: 10.5755/j01.u.65.2.17151