

Ultrasonographic evaluation of the eye parameters in dogs of different age

A.Paunksnis¹, E. Svaldenienė², M. Paunksnienė², V. Babrauskienė²

¹ *Institute for Biomedical research, University of Medicine, Kaunas Lithuania*

² *Department of anatomy and histology, Veterinary Academy, Kaunas Lithuania*

Introduction:

Ultrasonography has been used since 1956 for diagnostic ocular diseases in humans. Veterinary ocular ultrasonography was first described in 1968 (13). The great advantage of ultrasound is the ability to evaluate the internal structure of the eye when refractive media (cornea, lens) are opaque (21). Knowledge of the dimensions of the optical components is required to better understand of many research and clinical problems in vision (24). This requirement is met in general by giving a quantitative description of the dioptrics of a typical eye (schematic or model eye). In humans the model eye could be used to determine spectacle lens power needed to correct a refractive error, intraocular lens power required after cataract surgery or to determine the refractive state (14). In veterinary medicine ocular biometry has potential application in establishing lens power, and estimating prosthetic globe size after enucleation (6, 7).

Both A-mode and B-mode ultrasound have been used for ocular biometry. A-mode was recognized as more accurate than B-mode in detecting small lesions of the eye and to group lesions in histopathologic differential diagnoses (13, 4).

Ocular dimensions varied considerably and depended on species, age, and sex (3, 4, 14, 16, 17, 21). Axial ocular length was significantly longer in human males than in females (13); the lens thickness was increased and anterior chamber depth was decreased with aging in both sexes in human (12). This was also found in the dog (21, 5). Later, it was reported that axial ocular length did not depend on age or sex, but was significantly greater in dogs of large breeds (6). Dolichocephalic breeds had a longer eye globe than did mesocephalic breeds (3). Ocular dimensions were measured for camel, cow, pig, sheep (14, 15, 16, 17, 19). The eye of the one-humped camel was smaller than of a horse, and cow but bigger than of a sheep, pig, dog and cat (14).

Ultrasonic pachymetry is the most accurate *in vivo* method (8, 9, 22). The hand-held ultrasonic instruments are precise, relatively simple clinical instrument to use and accurately measure the thickness in any area of the cornea (11).

Some studies showed the cornea of the human, dog, horse and cow was thinner in the center and thicker at the periphery (19, 22). The cornea of the cat was uniform (9, 22). The central part of the porcine cornea was slightly thicker than peripheral part; in bulls, peripheral superior area was thickest and the peripheral temporal location was the thinnest (8, 23, 18). Other authors reported that the peripheral cornea of the dog was thicker than the central and that corneal thickness increased with age (7, 8). The

thickness of cat cornea increased with age up to 100 month, then leveled off and slightly decreased (9).

According to all reports the corneas of the left and right eye did not differ significantly (5, 8, 18, 19, 22, 23).

Materials and methods:

The aim of this study was to measure and evaluate *in vivo* the structures of the eye (the thickness of the cornea, lens, and vitreous, and sagittal eyeball axis) in dogs of different age using ultrasound equipment.

The twenty-eight mixed-breed dogs of different age were used in this study. We investigated five 10 to 15-days-old puppies, weighing 0.4 – 0.6 kg (group no. 1), five 20-day-old puppies, weighing 0.3 – 0.5 kg (group no. 2), eight 2 to 4-month-old puppies, weighing 2.3 – 6.3 kg (group no.3), and ten adult dogs, weighing 7 – 9.5 kg (group no. 4). All dogs had a pre-study ophthalmic examination that demonstrated dog's eyes were normal. Dogs were sedated intramuscularly with mixture of Xylazin and Imalgen. The thickness of the lens, vitreous and sagittal eyeball axis were measured by A-mode ultrasonography (12) in all dogs.

The corneal thickness was measured using a 15 MHz fluid probe ultrasonic pachymetry in all dogs except those in the group 3. The corneal thickness of the young dogs (group 1 and 2) was measured in the central point of the cornea. We were unable to measure more points because of the cornea size. We measured five points in the adult dogs' cornea: central, peripheral superior, peripheral inferior, peripheral nasal and peripheral temporal. The peripheral points were 1 mm from limbus (the junction of cornea and sclera). Ten measurements were taken at each point to determine the mean thickness.

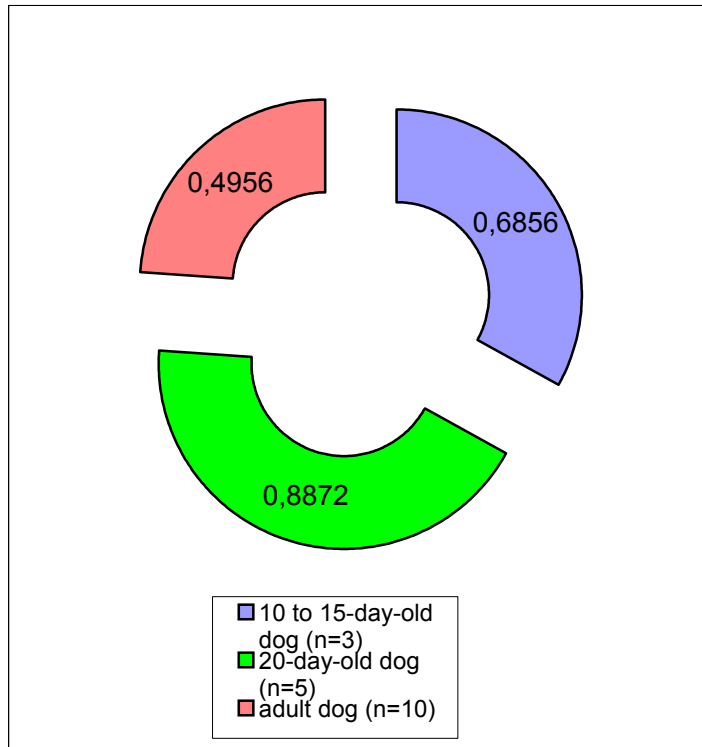
Measurements of the corneal thickness were grouped and compared by age of the dogs and measurement site. A Student t-test was used for statistical analysis.

Results:

We found that parameters of the eye such as the lens thickness, vitreous thickness and sagittal eyeball axis increased with age (Table 1). The lens thickness ranged from 2.1 to 3.1 mm in the group 1, from 2.2 to 4.2 mm in the group 2, from 2.3 to 4.7 mm in the group 3, and from 4.7 to 6.8 in the group 4. The vitreous thickness ranged respectively from 4.8 to 5.5 mm, from 4.6 to 5.7 mm, from 6.1 to 8.7 mm, and from 7.6 to 9.7 mm. Sagittal eyeball axis ranged from 10.1 to 11.4 mm, from 9.5 to 10.9 mm, from 13.3 to 18.5 mm, and from 18.5 to 20.6 mm respectively. The parameters of the left and right eye differed insignificantly.

The thickest central cornea was in the group 2 (Fig. 1) – mean corneal thickness was 0.8872 ± 0.1181 in the left eye and 0.9924 ± 0.1044 in the right eye. Corneal thickness

Left eye



Right eye

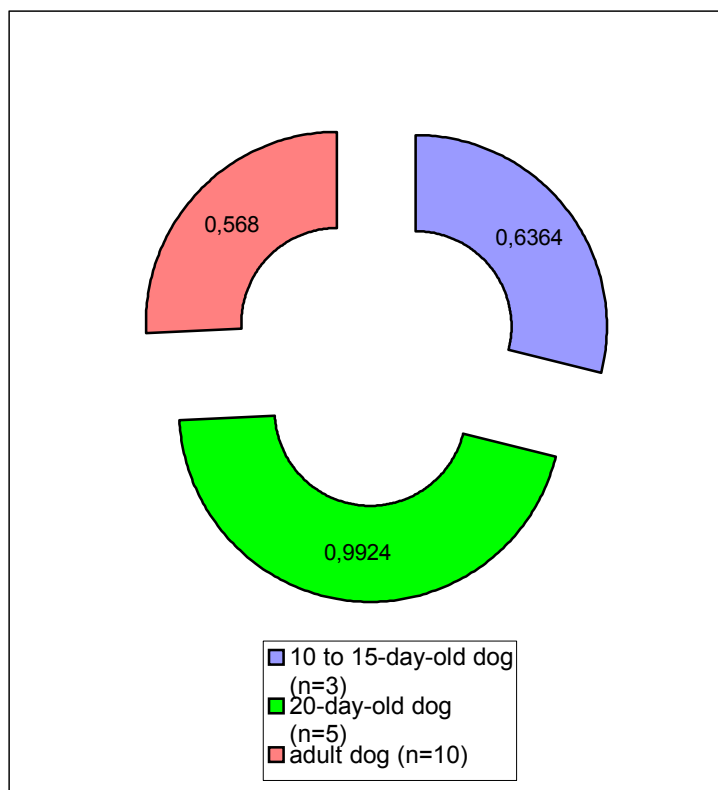


Fig. 1. Central corneal thickness in dogs of different age (group 1, 2 and, - 4)

Table 1. Measurements of the eye parameters in dogs of different age (mm) (mean±SD)

Group No.	Left eye			Right eye		
	Lens thickness	Vitreous thickness	Sagittal axis	Lens thickness	Vitreous thickness	Sagittal axis
1 (n=5)	2.38±0.421	5.20±0.123	10.48±0.536	2.44±0.305	5.06±0.321	10.62±0.476
2 (n=5)	3.14±0.627	5.06±0.089	10.6±0.41	3.08±0.746	5.14±0.398	10.22±0.497
3 (n=8)	3.23±0.632	6.95±0.958	15.45±1.624	3.13±0.892	6.95±0.923	15.58±1.951
4 (n=10)	5.84±0.606	8.64±0.550	19.48±0.982	5.54±0.807	8.54±0.599	19.88±0.541

ranged from 0.7791 to 1.1396 mm in this group. The thinnest central cornea was in the group 4 (Fig. 1)– mean corneal thickness was 0.4956±0.1167 mm in the left eye and 0.568±0.0843 mm in the right eye. Corneal thickness ranged from 0.3432 to 0.7191 mm in this group. The central cornea in the group 1 was slightly thinner than in the group 2 (Fig. 1) – mean corneal thickness was 0.6856±0.0401 mm in the left eye and 0.6364±0.0148 mm in the right eye. In this group corneal thickness ranged from 0.629 to 0.7385 mm. The corneal thickness of the left and right eye differed insignificantly.

The central part of the cornea was the thinnest and peripheral part was slightly thicker in adult dog (group 4) The peripheral temporal point of the cornea was the thickest (Table 2).

Table 2. Corneal thickness (mm) in adult dogs (mean±SD)

Measurement site	Left eye	Right eye
Central	0.4956±0.1167	0.568±0.0843
Peripheral superior	0.5455±0.0999	0.06106±0.0972
Peripheral inferior	0.5906±0.0805	0.6178±0.0751
Peripheral nasal	0.6207±0.0780	0.6253±0.0560
Peripheral temporal	0.6426±0.0821	0.6260±0.0543

Discussion:

Various aspects of ageing of the eye have been investigated in different mammals. The sagittal growth of different parts of the eye is of interest for understanding the development of refractive errors and age-related diseases, such as primary angle-closure glaucoma. The sagittal growth of the normal eye and intraocular structures have been studied in humans, rhesus monkey, tree shrews, pigs and dogs from 2 month to 13 years (5, 11, 15, 16). We investigated the changes of normal eye structures from the opening of the eye cleft (10 to 15-day-old puppies) to full eye development (adult dogs). The lens thickness, vitreous thickness and sagittal eyeball axis increased with age. The parameters of the left and right eye differed insignificantly.

Reports of canine corneal thickness are conflicting. According to some reports (5, 10) the corneal thickness increased throughout the dog's life; initially it grew rapidly, but later it grew more slowly. We found that the

cornea of 20-day-old dogs was the thickest. The corneas of 10 to 15-day-old dog were slightly thinner and the corneas of adult dogs were the thinnest. The measurements of the anterior department of the eye - cornea, anterior chamber and lens – might be impeded by the cornea's close position to the lens in such young dog (10 to 20-day-old dog). This may cause errors of cornea thickness measurements. Investigations of thickness and structure of young dogs (after eye cleft opening) are continued.

The thickness of canine cornea is not uniform. Some authors report that the central cornea is thicker than the peripheral (20), others have reported the contrary (8, 17, 21). We found that the central part of the adult dog's cornea was thinner than the peripheral part and the peripheral temporal point was the thickest.

Conclusions:

The lens thickness, vitreous thickness and sagittal eyeball axis depended on dogs' age. The thickest cornea was in 20-day-old dogs, the thinnest – in adult dogs. Parameters of the left and right eye differed insignificantly.

Corneal thickness was not uniform in adult dogs. The central part of the cornea was the thinnest, peripheral part was thicker.

References:

1. Babrauskienė V. Kiaulių ragenos struktūros amžinių pokyčių analizė. Veterinarija ir zootechnika. 1997. T. 3(25). P.13-14.
2. Babrauskienė V., Paunksniėnė M. Kiaulių ragenos storio ypatybės. Veterinarija ir zootechnika. 1997. T. 4(26). P.5-6.
3. Cottrill N. B., Banks W. J., Pechman R. D. Ultrasonographic and biometric evaluation of the eye and orbit of dogs. Am J Vet Res. 1989. Vol.50, No.6. P.898-903.
4. Ekesten B. Biological variability and measurement error variability in ocular biometry in Samoyed dogs. Acta vet. Scand. 1994. Vol.35. P.427-433.
5. Ekesten B. Primary glaucoma in the Samoyed dog. Dissertation.1994. P.29-35.
6. Gaiddon J., Rosolen S. G. et al. Use of biometry and keratometry for determining optimal power for intraocular lens implants in dogs. Am J Vet Res. Vol. 52, No.5. P.781-783.
7. Gilger B. C., Davidson M. G., Howard P. B. Keratometry, ultrasonic biometry, and prediction of intraocular lens power in the feline eye. Am J Vet Res. 1998. Vol. 59, No. 2. P.131-134.

8. **Gilger B. C., Whitley R. D. et al.** Canine corneal thickness measured by ultrasonic pachymetry. *Am J Vet Res.* 1991. Vol.52, No.10. P.1570-1572.
9. **Gilger B. C., Wright J. C. et al.** Corneal thickness measured by ultrasonic pachymetry in cats. *Am J Vet Res.* 1993. Vol.52, No.2. P.228-230.
10. **Gwin R. M., Lerner I. Et al.** Decrease in canine corneal endothelial cell density and increase in corneal thickness as function of age. *Invest Ophthalmol Vis Sci.* 1982. Vol.22. P.267-271.
11. **Kremer F. B., Walton P., Gensheimer G.** Determination of corneal thickness using ultrasonic pachometry. *Ann Ophthalmol.* 1985. P.506-507.
12. **Lim K. J., Hyung S. M., Youn D. H.** Ocular dimensions with aging in normal eyes. *Korean. J. Ophthalmol.* 1992. Vol.6. P.19-31.
13. **Nyland T. G., Mattoon J. S.** Veterinary diagnostic ultrasound. W.B. Saunders company. 1995. P.178-197.
14. **Osuobeni E. P., Hamidzada W. A.** Ultrasonographic determination of the dimensions of ocular components in enucleated eyes of the one-humped camel//*Research in veterinary science.* 1999. Vol.67. P.125-129.
15. **Paunksnienė M., Babrauskienė V.** Structural peculiarities of domestic eye tunics. *Veterinarija ir zootechnika.* 1996. T.1(23). P.90-94.
16. **Paunksnienė M., Babrauskienė V., Paunksnis A.** Ultrasonographic evaluation of animal eye dimensions. *Veterinarija ir zootechnika.* 1997. T.3(25). P.29-33.
17. **Paunksnienė M., Paunksnis A., Babrauskienė V., Lukoševičius A.** Ultrasonic measurements of animal eye dimensions. *Acta veterinaria Baltica.* 1996. P.42-44.
18. **Paunksnis A., Svaldenienė E., Babrauskienė V., Paunksnienė M.** Ragenos storio matavimas ultragarsu// *Medicina.* 1999. T.35. P.336-341.
19. **Ramsey D. T., Hauptman J. G., Petersen-Jones S. M.** Corneal thickness, intraocular pressure, and optical corneal diameter in Rocky Mountain horses with cornea globosa or clinically normal corneas. *Am J Vet Res.* 1999. Vol.60, No.10. P.1317-1321.
20. **Prince J. H., Diesen C. D. et al.** Anatomy and histology of the eye and orbit in domestic animals. Springfield: Charles C Thomas, Publisher. 1960. P.73
21. **Schiffer S. P., Rantanen N. W. et al.** Biometric study of the canine eye, using A-mode ultrasonography. *Am J Vet Res.* 1982. Vol.43, No.5. P.826-830.
22. **Schoster J. V., Wickman L., Stuhr C.** The use of ultrasonic pachymetry and computer enhancement to illustrate the collective corneal thickness profile of 25 cats. *Veterinary & comparative ophthalmology.* 1995. Vol.5, No.2. P.68-73.
23. **Svaldenienė E., Paunksnienė M., Babrauskienė V.** Canine corneal thickness peculiarities in vivo and after eye ball enucleation. *Veterinarija ir zootechnika.* 1998. T.6(28). P.38-40.
24. **Wong T. Y., Foster P. J. et al.** Variations in ocular biometry in adult Chinese population in Singapore: the Tanjong Pagar Survey. *Invest. Ophthalmol. Vis. Sci.* 2001. Vol.42. P.73-80.

A.Paunksnis, E. Svaldenienė, M. Paunksnienė, V. Babrauskienė

Įvairaus amžiaus šunų akių matmenų ultragarsinis įvertinimas

Reziumė

Šio tyrimo tikslas buvo išmatuoti ir įvertinti įvairaus amžiaus šunų akių elementus – ragenos storį, lęšio bei stiklakūnio storį ir sagitalinės akies ašies ilgį. Tyrimams naudojome mišrūnus 10-15 dienų, 20 dienų, 2-4 mėnesių amžiaus šuniukus ir suaugusius šunis. Tyrimo metu naudojome ultragarsinę aparatūrą. Nustatėmė, kad lęšio bei stiklakūnio storis ir sagitalinės akies ašies ilgis su amžiumi didėja. Kairės ir dešinės akies matmenys skiriasi nežymiai. Centrinė ragena storiausia buvo 20 dienų amžiaus šunims (kairėje akyje - 0.8872 ± 0.1181 mm, dešinėje - 0.9924 ± 0.1044 mm), 10-15 dienų šunų ragena truputėlį plonesnė, ploniausia buvo suaugusių šunų ragena (kairėje akyje - 0.4956 ± 0.1167 mm ir dešinėje - 0.568 ± 0.0843 mm). Suaugusių šunų ragenos storis nėra vienodas – abiejų akių centrinė ragenos dalis yra plonesnė nei periferinė. Storiausias yra periferinis temporalinis ragenos taškas.

Šį darbą finansuoja Lietuvos valstybinis mokslo ir studijų fondas.

Pateikta spaudai 2001 05 14

DOI: 10.5755/j01.u.39.2.8056