

Color Doppler imaging of retrobulbar hemodynamics in normal tension glaucoma patients and normal controls

I. Janulevičienė¹, L. Kuzmienė¹, A. Cimbalas², A. Paunksnis², V. Barzdžiukas¹

1 Eye Clinic of Kaunas University of Medicine

Eivenių 2, Lt – 3007 Kaunas, Lithuania

2 Department of Ophthalmology of Institute for Biomedical Research of Kaunas University of Medicine

Eivenių 4, Lt – 3007 Kaunas, Lithuania

Introduction

Glaucoma is one of the main reasons of irreversible blindness in the world. It is characterised as multifactorial progressive optic neuropathy with typical changes in the optic disc and visual field [1]. Although glaucoma clinical picture is well described and analysed, little is known about ethiopathological mechanisms leading to these specific changes. Meanwhile, a number of major risk factors are well known. Some of them can not be influenced – such as age, gender, refraction and race. Others – such as intraocular pressure (IOP) and vascular disregulation can be influenced. Influence on these factors can preserve sight and help to escape blindness.

Two principal theories in the pathogenesis of glaucomatous optic neuropathy (GON) have been described: a mechanical and a vascular theory. Both have been defended by various research groups over the past 150 years [2]. According to the mechanical theory, increased intraocular pressure (IOP) causes stretching of the laminar beams and damage to retinal ganglion cell axons. The vascular theory of glaucoma considers GON as a consequence of insufficient blood supply due to either increased IOP or other risk factors reducing ocular blood flow (OBF). Normal tension glaucoma (NTG) is a paradox for the mechanical theories of GON. In patients with NTG loss of visual function and progressive damage of the nerve fiber layer occur despite their normal IOP measurements. These patients would indicate that raised IOP is not the primary cause of damage to the optic nerve head. Besides that NTG patients rather often have systemic vascular disregulation: arterial hypotension, vasospasms, migraine, etc [3]. The fact that the reduction of OBF often precedes the damage and blood flow can also be reduced in other parts of the body of glaucoma patients, indicate that the hemodynamic alterations may at least partially be primary. The major cause of this reduction is not atherosclerosis, but rather a vascular disregulation, leading to both low perfusion pressure and insufficient autoregulation. This in turn may lead to unstable ocular perfusion and thereby to ischaemia and reperfusion damage.

The aim of glaucoma medical therapy is to lower the IOP and increase ocular perfusion dynamics, preserving visual function [3]. It is extremely complicated to evaluate the effect of NTG treatment. The IOP lowering effect can be evaluated mostly by ocular functional parameters. There are data that changes in retrobulbar hemodynamics can be

detected prior to clinical glaucomatous changes [4]. Color Doppler imaging (CDI) is an ultrasound technique that combines B-scan gray scale imaging of tissue structure, color representation of blood flow based on Doppler shift and pulsed Doppler measurement of blood flow velocities. In ophthalmology it is used to measure blood flow velocity in the retrobulbar vessels, using 5-7,5 MHz frequency transducers.

The main objectives of our work was to evaluate retrobulbar hemodynamics in ophthalmic artery in NTG patients and age-matched controls and to evaluate the effect of initial IOP lowering treatment.

Materials and methods

Twenty patients (40 eyes) with newly diagnosed NTG and 30 healthy age-matched controls (60 eyes) were enrolled in the study. For the purposes of investigation glaucoma was defined as characteristic glaucomatous visual field loss and optic nerve head damage with IOP not greater than 21 mmHg which was determined by Schoetz impression tonometry. None of the subjects had a mean deviation greater than 20dB of visual fields measured by Humphrey Visual Field Analyser central 30-2 and/or cup to disc ratio greater or equal 0,7. Best corrected visual acuity was 0,8 or better.

All the subjects answered the standard questionnaire for main glaucoma risk factors. The following eye examination was carried out: visual acuity, visual field examination, impression tonometry, biomicroscopy and gonioscopy, fundus examination with 78D lens. OBF examination was performed using UDD 03 developed on the bases of IBM PC 386 (Kaunas University of Technology) working in CDI mode for investigation of peripheral vessels. This instrument measures automatically peak systolic (V syst) and end-diastolic (V diast) velocities, Gosling pulsatility (PI) and Pourcelot resistivity (RI) indices. The maximum measuring depth – 35 mm. Intensity of ultrasound < 15 mW/cm². 7 MHz frequency transducer was used. The same qualified investigator carried out the CDI measurements as reliability and reproducibility of the results also depend on the experience of the user. Fig.1 shows CDI of the ophthalmic artery of the eye with NTG.

Initial treatment of newly diagnosed NTG we started with β blockers once daily (0,5% Timoptic XE solution

®). After 4 weeks of treatment IOP and CDI measurements were repeated.

Statistical analysis was performed using “Microsoft Excel 2000”, “Statistica 5.0”.

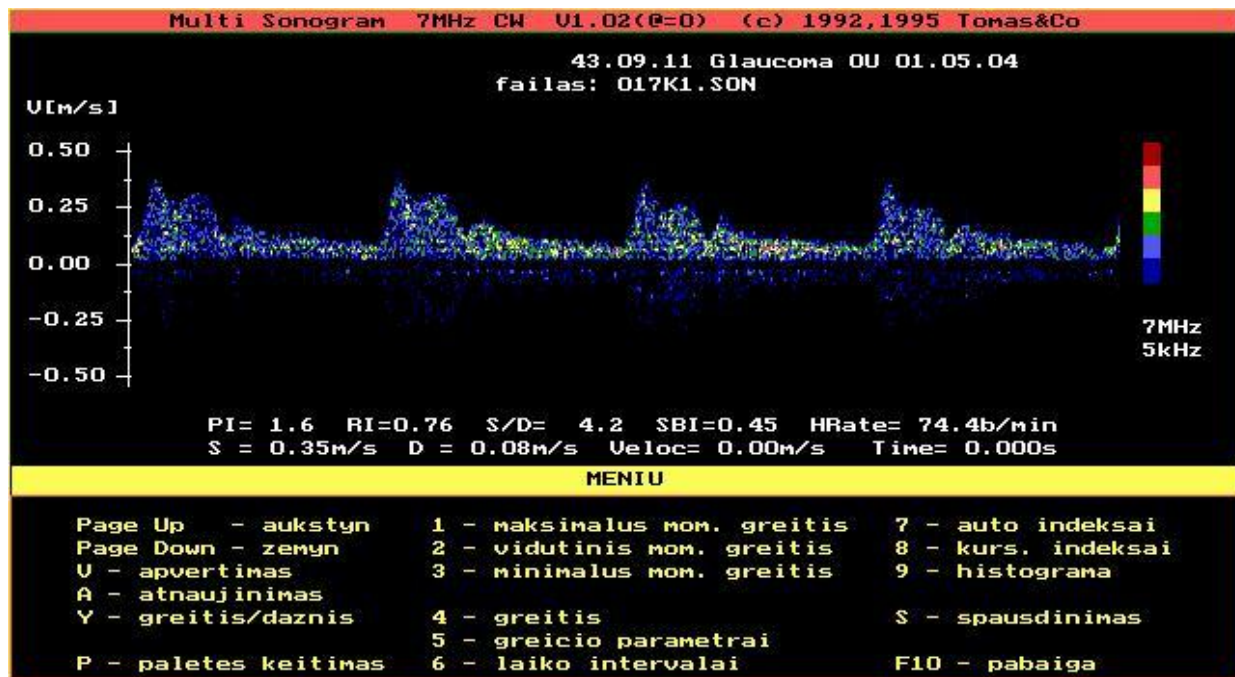


Fig.1. CDI of the ophthalmic artery of the NTG eye

Results and discussion

Age and sex of NTG patients and normal control subjects are shown in Table 1. There is evidence that glaucoma increases with age [13]. In our study the mean age of NTG patients was 51.9 years. There were no significant differences between the groups according to the age and sex. NTG is more common in women than in men [12]. In our study the NTG group included 60% women.

Questionnaire of glaucoma risk factors (Table 2) revealed that arterial hypotension was more common in NTG group and the difference was significant. Primary open angle glaucoma and normal tension glaucoma are usually more common in patients with arterial hypotension

[18], peripheral vasospasm [19], myocardial infarction [20], cerebral ischaemia and migraine[21]. In our study all above mentioned glaucoma risk factors were predominating in NTG group compared to normal controls ($p<0,05$). Healthy hyperopic and myopic eyes have the same mean IOP as emmetropic eyes, but myopia is frequently more common in open angle glaucoma [33]. In our study myopia was more common in NTG group than in healthy controls ($p<0,05$).

In some studies family background – is considered as glaucoma risk factor [33]. In NTG group family glaucoma history was found in 10% of patients and there was no family glaucoma in control group.

Table 1. Main characteristics of study subjects

Risk factors	NTG patients	Normal controls	p
Age (X±SD)	51,9 ±9,56	50 ±6,4	NS
Male N (%)	8 (40%)	11 (36,7%)	NS
Female N (%)	12 (60%)	19 (63,3%)	NS
Total N (%)	20 (100%)	30 (100%)	-

Table 2. Comparison of glaucoma risk factors among study subjects

Risk factors	NTG patients N (%)	Normal controls N (%)	p
Arterial hypotension	9 (45%)	1 (3,3%)	<0,05
Family glaucoma history	2 (10%)	0	-
Migraine	2 (10%)	1 (3,3%)	<0,05
Myocardial infarction	1 (5%)	0	-
Myopia	5 (25%)	2 (6,7%)	<0,05

Table 3. Comparison of blood flow velocity in the ophthalmic artery between NTG patients and control subjects

Variable	NTG patients	Normal controls	p
V _{syst} [cm/s]	25,69±6,34	31,37±6,48	<0,05
V _{diast} [cm/s]	6,01±2,90	5,67±5,67	NS
PI	1,24±0,51	1,38±0,44	NS
RI	0,79±0,09	0,82±0,09	NS

Table 4. Comparison of blood flow velocity in the ophthalmic artery in NTG patients before and after treatment

Variable	Before treatment	After treatment	p
V _{syst} [cm/s]	25,69±6,34	29,85±7,34	<0,05
V _{diast} [cm/s]	6,01±2,90	8,39±4,38	<0,05
PI	1,24±0,51	1,65±0,62	<0,05
RI	0,79±0,09	0,69±0,18	<0,05

For a long time glaucoma studies were focused only on evaluation of IOP [6], but the pathogenesis of glaucoma cannot be explained only by mechanical theory [7,8,9,10,11,15] as the blood supply of the optic nerve, especially of the head of the optic nerve is important in the development of glaucomatous changes. In our study we chose patients with newly diagnosed normal tension glaucoma. The mean intraocular pressure (IOP) was higher in NTG group compared to normal controls, but the difference was not significant (18,6±1,3 mmHg and 16,4±2,1 mmHg; NS).

In recent years many studies discuss the retrobulbar blood flow parameters [23,24,25,26,27]. CDI is a quantitative and qualitative method in evaluation of retrobulbar blood flow. In our work we used the CDI to evaluate blood flow only in the ophthalmic artery. Data are presented in Table 3.

Initial treatment of newly diagnosed NTG we started with β blockers once daily (0,5% Timoptic XE solution ®). After 4 weeks of this kind of treatment there was significant decrease in IOP (from 18,6±1,3 to 14,6±1,4; p<0,05). As there are studies showing that progression of glaucomatous changes have low relationship with IOP [14], the aim of our study was to evaluate shift of ocular blood flow parameters using CDI. According to our data 0,5% Timoptic XE solution ® significantly increased blood flow velocities and PI, decreased RI.

To summarize the findings of OBF studies in glaucoma is difficult for the reasons that authors use different techniques and therefore measuring different eye vessels, different glaucoma stages (e.g. early vs. late) and different types of glaucoma are studied (e.g. NTG vs. primary open angle glaucoma) [26]. Nevertheless, the vast majority of studies published find on average a reduced ocular perfusion in glaucoma patients. Blood flow decreases with increasing damage, however the reduction occurs in both early and late stages of glaucoma [24]. Blood flow disturbances generally seem to be more pronounced in NTG than high IOP glaucoma [27]. Finally blood flow reduction is more pronounced in progressive than non-progressive eyes [24]. Further investigations of OBF are needed to evaluate disturbances of perfusion with respect to visual functions.

Conclusions:

1. The peak systolic blood flow velocity was significantly higher in normal control group compared to NTG patients group.
2. The initial 4 week treatment with 0,5% Timoptic XE solution ® increased blood flow velocities and PI, decreased RI in the ophthalmic artery of NTG patients.
3. Further investigations of small optic nerve blood vessels could provide more evidence about the role of vascular factors in glaucoma patients.

References

1. Van Buskirk E. M, Cioffi G. A. Glaucomatous optic neuropathy. *Am. J. Ophthalmol.* 1992. Vol.113. P.447-452.
2. Fechtner R. D, Weinreb R. N. Mechanisms of optic nerve damage in primary open angle glaucoma. *Surv. Ophthalmol.* 1994. Vol.39. P.23-42.
3. Robin A. L, Barnebey H. S, Harris A, Osborne N. Glaucoma management: beyond intraocular pressure. *Ophthalmology Times.* 1997. Vol.22 (suppl). S1-23.
4. Nicoleta M. T, Drance S. M, Rankin S. J et al. Color Doppler imaging in patients with asymmetric glaucoma and unilateral visual field loss. *Am. J. Ophthalmol.* 1996. Vol.121. P.502-10.
5. Delay C., Van de Voorde J. Regulatory mechanisms in the retinal and choroidal circulation. *Ophthalmic Res.* 2000. Vol.32. P.249-256.
6. Crick R. P, Vogel R, Newson R. B. et al. Relationship between intraocular pressure and visual field progress in chronic simple glaucoma and ocular hypertension. *Glaucoma.* 1985. Vol.7. P.208-219.
7. Sommer A., Tielsch J. M, Katz J., Quigley H. A. et al. The Baltimore Eye Survey. Relationship between intraocular pressure and primary open angle glaucoma between white and black Americans. *Arch. ophthalmol.* 1991. Vol.109. P.1090-1095.
8. Rossetti L., Marchetti I., Orzalesi N. et al. Randomised clinical trials on medical treatment of glaucoma. Are they appropriate to guide clinical practice? *Arch. Ophthalmol.* 1993. Vol.111. P.96-103.
9. Chauhan B. C. The relationship between intraocular pressure and visual field progression in glaucoma. In Drance SM (ed). *Update to Glaucoma, Blood Flow and Drug Treatment.* Amsterdam. Kugler. 1995. P.1-6.
10. Collaborative Normal Tension Study Group. Comparison of glaucomatous progression between untreated patients with normal tension glaucoma and patients with therapeutically reduced intraocular pressure. *Am. J. Ophthalmol.* 1998. Vol.126. P.487-497.
11. Collaborative Normal Tension Study Group. The effectiveness of intraocular pressure reduction in the treatment of normal tension glaucoma. *Am. J. Ophthalmol.* 1998. Vol.126. P.498-505.

12. **Orgul S, Flammer J, Gasser P.** Female preponderance in normal tension glaucoma. *Ann. ophthalmol. Glaucoma.* 1995. Vol.27. P.355-359.
 13. **Shiose Y, Kitazawa Y, Tsukahara S, Akamitsu T, Mizokami F, Futa R et al.** Epidemiology of glaucoma in Japan – a nationwide glaucoma survey. *Jpn. J. Ophthalmol.* 1991. Vol.35. P.133-155.
 14. **Weber J, Koll W, Krieglstein G. K.** Intraocular pressure and visual field decay in chronic glaucoma. *Ger. J. Ophthalmol.* 1993. Vol.2. P.165-169.
 15. **Messmer C, Flammer J, Stumpf D.** Influence of betaxolol and timolol on visual fields of patients with glaucoma. *Am. J. Ophthalmol.* 1991. Vol.112. P.678-681.
 16. **Flammer J, Gasser P, Prunte C, Yao K.** The probable involvement of factors other than ocular pressure in the pathogenesis of glaucoma. In: *Pharmacology of glaucoma.* S. M. Drance, E. M. Van Buskirk, A. H. Neufeld. Ed. Williams and Wilkins. Baltimore. P.273-283.
 17. **Orgul S., Flammer J.** Optic disc haemorrhages. *Neuroophthalmol.* 1994. Vol.14. P.97-101.
 18. **Hayreh S. S., Zimmermann B. M., Podhajsky P., Alward W. L. M.** Nocturnal arterial hypotension and its role in optic nerve head and ocular ischemic disorders. *Am. J. Ophthalmol.* 1994. Vol.117. P.603-824.
 19. **Flammer J.** The vascular concept in glaucoma. *Surv. Ophthalmol.* 1994. Vol.38. P.3-6.
 20. **Kaiser H. J., Flammer J., Burchhardt D.** Silent myocardial ischemia in glaucoma patients. *Ophthalmology.* 1993. Vol.207. P.6-8.
 21. **Stroman G. A., Stewart W. C., Golnik K. C., Cure J. K., Olinger R.** Magnetic resonance imaging in patients with low-tension glaucoma. *Arch. Ophthalmol.* 1995. Vol.113. P.168-172.
 22. **Bron A.** Neuroprotection in the eye: what's on the horizon? In: *Pharmacotherapy in Glaucoma.* Ed. S. Orgul, J. Flammer. Verlag Hans Huber. 2000. P.293-301.
 23. **O'Brien C., Mckillop G. et al.** Color Doppler imaging in untreated high- and normal-pressure open-angle glaucoma. *Invest Ophthalmol Vis Sci.* 1997. Vol.38. P.690-696.
 24. **Yamazaki Y., Drance S. M.** The relationship between progression of visual field defects and retrobulbar circulation in patients with glaucoma. *Am. J. Ophthalmol.* 1997. Vol.124. P.287-295.
 25. **Costa V. P., Sergott R. C., Smith M., Spaeth G. L. et al.** Color Doppler imaging in glaucoma patients with asymmetric optic cups. *J. Glaucoma.* Vol.3 (Suppl.1). S91-S97.
 26. **O'Brien C., Harris A.** Optic Nerve Blood Flow Measurement. In Yanoff M., Duker J. S. (ed) *Ophthalmology.* Mosby Int. Ltd. 1999.
 27. **Harris A., Sergott R. C., Spaeth G. L., Katz J. L. et al.** Color Doppler analysis of ocular blood velocity in normal-tension glaucoma. *Am. J. Ophthalmol.* 1994. Vol.118. P.642-649.
 28. **Yoles E., Muler S., Schwartz M. et al.** Injury induced secondary degeneration of rat optic nerve can be attenuated by adrenoceptor agonists AGN 191103 and brimonidine. *Invest Ophthalmol Vis Sci.* 1996. Vol.37 (3 Suppl). S114.
 29. **Harris A., Arend O. Chung H. S. et al.** A comparative study of betaxolol and dorsolamide on the ocular circulations in normal-tension glaucoma patients. *Ophthalmology.* 2000. Vol.107. P.430-434.
 30. **Steffansson E., Jensen P. K., Eysteinnsson T. et al.** Optic nerve oxygen tension in pigs and the effect of carbonic anhydrase inhibitors. *Invest Ophthalmol Vis Sci.* 1999. Vol.40. P.2756-2761.
 31. **Harris A., Arend O., Kagemann L. et al.** Dorsolamide, visual function and ocular hemodynamics in normal-tension glaucoma. *J Ocular Pharm and Therapeutics.* 1999. Vol.15. P.189-197.
 32. **Sponsel W. E., Harrison J., Elliot W. R., Trigo Y. et al.** Dorsolamide hydrochloride and visual function in normal eyes. *Am. J. Ophthalmol.* 1997. Vol.123. P.759-766.
 33. **Flammer J.** *Glaucoma.* Verlag Hans Huber. First edition. 2001.
- I. Janulevičienė, L. Kuzmienė, A. Cimbalas, A. Paunksnis, V. Barzdžiukas
- Retrobulbarinės akies kraujotakos tyrimas: lyginamieji sveikų ir normalaus akispūdzio glaukoma sergančių asmenų duomenys**
- Reziumė
- Straipsnyje pateikiami sveikų ir normalaus akispūdzio glaukoma sergančių asmenų retrobulbarinės akies kraujotakos tyrimo palyginamieji duomenys. Akinės arterijos doplerografija atlikta naudojant ultragarsinį kraujo tėkmės matavimo aparatą. Kauno Technologijos universitete pritaikyta periferinių kraujagyslių matavimams (UDD –0,3 su IBM PC 386). Vertinti akinės arterijos kraujo tėkmės sistolės ir diastolės greičiai, Pourcelot rezistentiškumo bei Gosling pulsacinis indeksai. Rezultatai rodo, kad glaukoma sergančių pacientų akies retrobulbarinė kraujotaka yra sutrikusi. Medikamentinis gydymas smarkiai sumažino rezistentiškumo indeksą, padidino diastolinį kraujo tėkmės greitį. Dėl to pagerėjo kraujo tėkmė akinėje arterijoje. Suregulius kraujotaką akinėje arterijoje, aprūpinančioje krauju tinklainės ganglines ląsteles, užkertamas kelias ischeminiams pakitimams tinklainėje, nežūva ganglinės ląstelės.

Pateikta spaudai 2002 12 17

DOI: 10.5755/j01.u.45.4.8152