

## Evaluation parameters and technique for classification of intraocular tumours

M. Žakauskas<sup>1</sup>, A. Mačiulis<sup>1</sup>, A. Kopustinskas<sup>1</sup>, A. Paunksnis<sup>2</sup>, D. Krivaitienė<sup>2</sup>

*1 Department of Applied Electronics, Kaunas University of Technology  
Studentų g. 50-327, LT-3031 Kaunas, Lithuania*

*2 Institute of Biomedical Research, Kaunas Medical University  
Eivenių g.4, LT-3007 Kaunas, Lithuania*

### Introduction

Classification and diagnosis of intraocular tumours is one of the actual problems in ophthalmology. Melanoma, metastasis and no malignant tumour are frequently observed intraocular tumours. Simply no malignant tumour in the text refers as “no tumour”. Melanoma is melanocytus neoplastic tumour, which may induce the secondary tumours (metastasis) to lungs, liver and bones. Melanoma commonly starts to grow in the eye posterior urea. Melanoma is the direct reason of death for each third patient. Therefore early diagnosis of this pathology is crucial for proper treatment and prognosis.

Ultrasound echographic technique is widely used for visualization of intraocular tumours. Non invasiveness, informativity and user-friendliness are the main features of ultrasound technique. The brightness of ultrasound image element (pixel) depends on the distribution of acoustic impedance or tissue density. The possibility of ultrasound technique applying for classification of various tumours is based on the direct relationship between tumour tissue density distribution and its morphology.

Set of publications is made on echographic characterization of intraocular tumours [1, 2, 3]. Ordinary method for analysis of echographic images is based on search and evaluation of specific parameters, statistical analysis and methods of image texture classification. A 15-year retrospective analysis of tumours classification is presented in [1]. Main echographic parameters are determined in [3]. Application of data mining technique for medical decision support is discussed in [4]. Fundamental technique for parametrisation of ultrasonic images is presented in [5]. The essence is to use the point spread function and inverse filtering technique for restoration of ultrasonic images. Further investigations are needed to show whether the use of complicated mathematical tools allows to reduce the image noises and gives a more useful information.

Analysis of publications shows that the possibilities of ordinary methods for tumour classification are not exhausted. It is desirable to search for new specific parameters, based on the information about the mechanism of image element genesis, to determine interrelationship and to increase the reliability of classification.

The aim of the present paper is to develop technique, to find optimal values of specified ultrasonic images parameters and investigate the system See5.0(C5.0) for classification of intraocular tumours.

### Method of investigation

All patients have been examined with the ultrasonic diagnostic imaging system Mentor Advent, using A/B scan mode.

The block diagram of the developed computerized ultrasound system for intraocular tumour image acquisition and analysis is shown in Fig.1. The focused transducer center frequency is 12,5 MHz, radius of the transducer – 2,7 mm, the scan range – 5 cm.

The images are transmitted from video output of the ultrasound system to PC by the use of a frame grabber. Captured echographic images were analysed using numerical computation and the visualization software MATLAB. Some statistical computations were performed by using Microsoft Office Excell 2000.

Echographic parameters for classification of eye tumours are obtained from ultrasonic A/B images. A-echogram presents the time (distance from transducer) function of an echo signal amplitude. B-echogram presents two dimensional distribution of an echo signal amplitude in the B-scan plane. A typical example of A/B image, obtained with above mentioned ultrasonic system is shown in Fig.2.

Following parameters of intraocular tumour are defined from echographic images: height, base, shape, the level of tumour compactivity, existing complications (hemorrhages, retinal detachments), internal reflectivity (the feature to reflect ultrasound waves), internal regularity (the feature of distribution of peak amplitudes throughout the tumour), choroidal excavation.

It is important to define allocation, size, complications and morphological type of an intraocular tumour. The final decision of the morphological type of the tumour was obtained after enucleating and invasive pathology investigations.

Structure and geometry of eye an tumour is shown in Fig. 3. The height and the base of tumour are measured during the patient eye examination, the height and base ratio is calculated. The shape, retinal detachment and choroidal excavation were determined from B-echographic images.

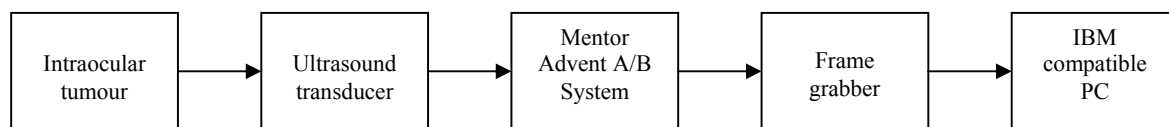


Fig. 1. Block diagram of the developed computerized ultrasound system for image acquisition and analysis

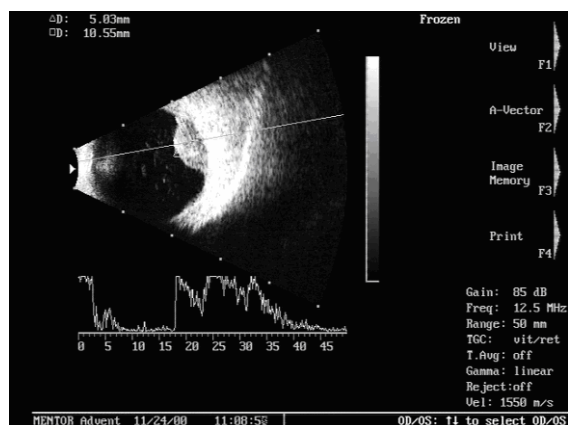


Fig. 2. Typical image, obtained with the ultrasound research MENTOR Advent A/B System

Others parameters were obtained by examination of A-echographic image.

The amplitude of an echosignal depends on the ratio of acoustic impedances of tissue or on the ratio of densities of tissue at the given point of image. The echosignal carries a valuable information about morphology of the tissue – shape, homogeneity and structure. Reflectivity of the tumour is characterized by the reflection coefficient  $K_A$  (%), which is calculated as a ratio of mean and maximal amplitudes of the echosignal:

$$K_A = \frac{R}{U_{\max}} - \frac{1}{m} \sum_{i=1}^m \frac{u_i}{U_{\max}} \times 100\%, \quad (1)$$

where  $u_i$  is the  $i$ -in value of the digitized echosignal amplitude, reflected by the tumour,  $U_{\max}$  is the maximal amplitude of the echosignal,  $m$  is the number of discrete points. Physically the reflectivity coefficient indicates the continuity of the distribution mean variations of the tumour tissue density. The three level system for evaluation of discrete values of the reflectivity coefficient was chosen: high, medium, low.

The regularity of an intraocular tumour tissue is characterized by the irregularity coefficient

$$K_R = \frac{\sqrt{\sum_{i=1}^m (x_i - \Delta x \cdot i)^2}}{L}, \quad (2)$$

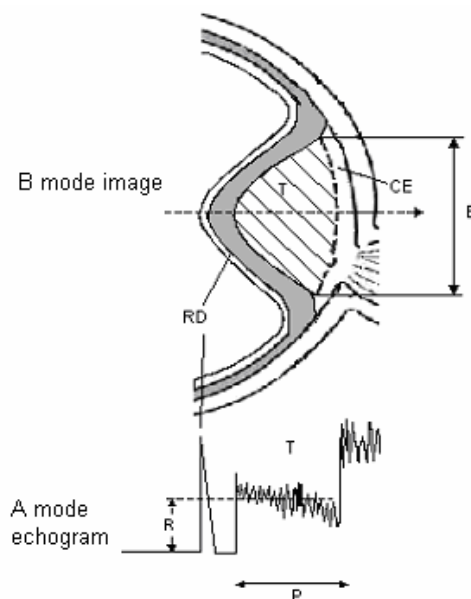


Fig.3. B-view of eye tumour (top), A echogram (below), T – tumour, RD – retinal detachment, CE – choroidal excavation, P- height of tumour, R – mean amplitude of reflected signal, B – base of tumour

where  $x_i$  is the position (mm) in  $A$  image of the  $i$ -th peak value of the echosignal,  $L$  is the length (mm) of a tumour in  $A$  image,  $m$  is the total number of peak values in the echosignal,  $\Delta x = L / m$  is the step of a regular tissue structure. The irregularity coefficient shows the continuity of distribution of maximal variation of tumour tissue densities.

### Statistical data

The database on 99 intraocular tumours for statistical analysis was stored in the laboratory of ophthalmology in the Institute of Biomedical Research of Kaunas Medical University Hospital during the period from 2000 to 2003. The ultrasound intraocular images database consists of 52 cases of melanoma, 8 – metastasis and 39 - no tumours.

The height and the base are comparable for all tumours and this is not a reliable statistically parameter for classification, but the height and base ratio characteristic of each group is statistically significant (see Fig.4). By the use of modified TNM (Tumor, Nodes, Metastasis) classification system all eye tumours are grouped accordingly to their

height into T1 (height no more 3,0 mm), T2 (height between 3,0 and 5,0 mm) and T3 (height more 5,0 mm) groups. The melanoma type tumours compose significant part in the T3 (65,4%) group, 13,5 % melanoma type tumours are found in the T1 group and 21,1% – T2 group. In the T3 group metastasis type tumour was undetected. Metastases often belong to the T1 (50 %) or to the T2 (50%) groups. No tumour type composes a significant part in the T1 (53,9 %) group, but this type may belong approximately equally to the T2 or T3 groups - respectively 25,6% and 20,5 %.

Interesting data were obtained analyzing the shape and others parameters of eye tumours.

In the melanoma group mushroom (50%) and dome (48,1%) shape types are main, the flat shape type occurs seldom, holey type – never. In the metastasis group tumours the mushroom shape type is not observed, there often could be seen dome (37,5 %) and holey (50%) shape type, the flat type occurs seldom (12,5%). In the group of no tumours the main is the dome shape type, the flat shape type is not observed.

The low (40,4%) and medium (59,6%) reflectivity coefficient is characteristic in the melanoma group. The medium 62,5%) and high (25%) reflectivity coefficient is dominating in the metastasis group. The medium (46,2%) and low (35,9%) reflectivity coefficient often can be seen in the group of no tumours.

No tumour group has a low level of regularity. The low regularity tissue has 61,5% from all no tumours. In metastasis and melanoma groups is characteristic high regularity structure, it has 75% and 65,4% tumours accordingly.

Choroidal excavation sometimes (18,6%) could be seen in the melanoma group, but in metastasis and no tumours groups clearly visible choroidal excavations are not found.

Correlations between classification parameters for various tumour groups are different in many cases. Statistically significant correlations are shown in Table 1.

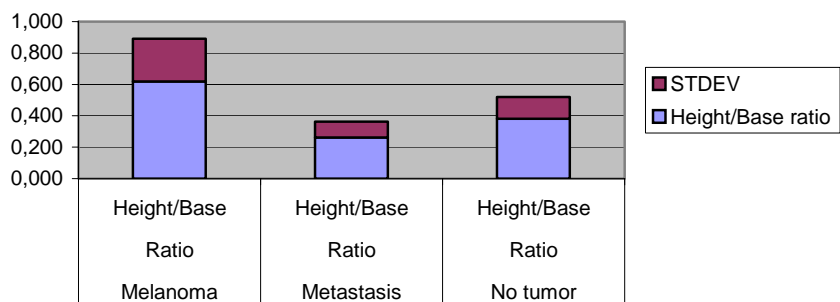


Fig. 4. Distribution of height and base ratio in different groups

Table 1. Correlation between classification parameters

Control group	Parameters of correlation	Coefficient of correlation
Melanoma	Between ratio hight/base and shape	0,48
	Between retinal detachment and hight	0,55
	Between ratio hight/base and $K_R$	0,39
Metastasis	Between shape and $K_R$	-0,69
	Between shape and ratio hight/base	-0,65
	Between base and choroidal excavation	0,65
	Between choroidal excavation and retinal detachment	-0,58
No tumour	Between $K_R$ and hight	0,73
	Between $K_R$ and ratio hight/base	0,45
	Between reflectivity and retinal detachment	-0,39

## Analysis of classification results

The program See 5.0/C5.0 was used for classification of intraocular tumours. RuleQuest Research Corp. distributes the version of program with one limitation – database for classifiers construction must be less than 400 samples. Performance of the program is based on the data mining system. Initial data with known conclusions (diagnosis) are used for the classifiers constructing. The decisions tree (see Fig.5) or classification rules are designed using these initial data. After that the classification is performed using new cases with an unknown diagnosis. Data attributes with continuous and/or digitized values can be used. Unnecessary attribute can be eliminated by a special command in parameters description file. Part of initial data or data file with unknown diagnosis can be used for investigation of classification reliability. There is possibility to determine which cases are classified inaccurately. The classifier is made using selected (decisions tree or/and classification rules) classification algorithm.

```

Results for band3
File Edit
Decision tree:
Shape = 1: Melanoma (16)
Shape = 2: Melanoma (1)
Shape = 3: No_tumor (4)
Shape = 0:
...Excavation = 1: Melanoma (5)
  Excavation = 0.5:
  ...Base <= 9.7: No_tumor (2)
  : Base > 9.7: Melanoma (2)
  Excavation = 0:
  ...Regularity = 0: No_tumor (13/1)
  Regularity = 1:
  ...Reflectivity = 0: Melanoma (5/1)
  Reflectivity = 1: No_tumor (4)
  Reflectivity = 0.5:
  ...Base <= 7.75: No_tumor (7/1)
  Base > 7.75: Melanoma (6)

Evaluation on training data (65 cases):

Decision Tree
-----
Size      Errors
-----
11        3( 4.6%) <<

(a) (b) <-classified as
-----
34   2 (a): class Melanoma
 1   28 (b): class No_tumor

```

Fig. 5. Example of intraocular tumours classification using classifier based on decision tree

Intraocular tumours were classified using four classifiers: decision tree, classification rules, corporate decision trees and corporate classification rules. Randomly picked 80 % of cases in databases were used for training of selected classifier and remainder 20% - for evaluation of the classifier reliability. 20 tests with each classifier with different set of intraocular tumours were performed and after the reliability was evaluated for the selected classifier.

The influence of different attributes to classification reliability was investigated. The digitized values of the reflectivity coefficient (low, medium, high) and the irregularity coefficient (regular, irregular) were used. "Tumour height" was eliminated as attribute in the database. In this case the reliability of classifiers had increased.

Tumours in the database were analyzed in three different ways:

- tumours were sorted into the malignant tumours, metastasis and no tumours;
- the malignant tumours and metastasis were treated as one class, no tumours - as another class;
- tumours are sorted into the malignant tumours and no tumours, the metastasis were eliminated.

The influence of the irregularity coefficient threshold value was investigated for differentiation of tumours into the regular and irregular groups. Values of the threshold were changed from 1.4 to 1.8 (see Fig. 6). The influence of reflectivity coefficient thresholds values was investigated for differentiation into the tumours with high, medium and low reflectivity as well.

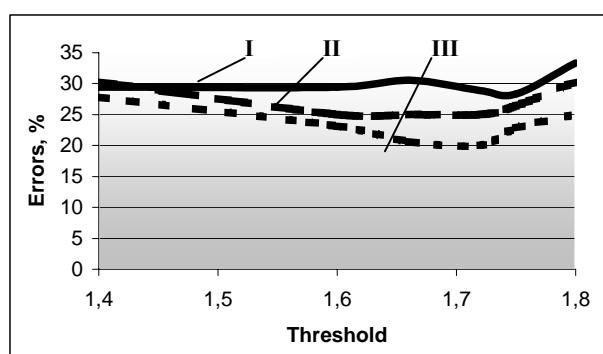


Fig. 6. Investigation of influence of the irregularity coefficient threshold value on classification reliability, there: I - classification results, when were selected values of reflectivity and irregularity coefficients; II - classification results, when were eliminated aberrant cases in the database; III - classification results, when were involved only tumours with a prominence higher than 2 mm

## Results

Investigation results show that the best reliability is found when digitized values of reflectivity and irregularity coefficients are used. The best classification accuracy is obtained when the thresholds values of the reflectivity coefficients  $K_A$  are 70% and 93% ( $K_A < 70\%$  - low reflectivity,  $70\% \leq K_A \leq 93\%$  - medium reflectivity,  $K_A > 93\%$  - high reflectivity) and the threshold value of the irregularity coefficient  $K_R$  is 1.72 ( $K_R \leq 1.72$  - regular tumour,  $K_R > 1.72$  - irregular tumour). These affirmations are right when classifiers are constructed using: decision tree, classification rules and corporate classification rules. When classifiers are constructed using the corporate decision trees, the thresholds values are slightly different. After initial investigation the thresholds values of the reflectivity coefficient  $K_A$  (70% and 93%) and the irregularity coefficient  $K_R$  (1.72) were selected. Investigations results are presented in Table 2.

Aberrant cases in the database were eliminated in order to obtain real classification results. These cases in the database probably could originate due to wrong diagnosis of physicians, inexperienced technician that made examination

of the patient, errors in calculation of tumours attributes (incorrect selection of A-echogram zone), low prominence of a tumour and etc. The classification results get better about 30% after 10 aberrant cases were eliminated from the tumours database (Table 2).

Verbeek and Thijssen [2] proposed not to take into the account the tumors with prominence less than 2mm. 15 cases

with such properties were eliminated from the tumours database. That improved reliability of the classification. After all these improvements, classification of tumours with 92% reliability was achieved (Table 2).

Table 2. Results of classification reliability investigations. These cases I, II and III are explained in heading of Fig.6

No	Classification rule	Tumours are sorted into the melanoma, metastasis and no tumours			Tumours are sorted into the melanoma and no tumours, metastasis ascribed as tumours			Tumours are sorted into the melanoma and no tumours, metastasis are eliminated		
		Errors, %			Errors, %			Errors, %		
		I	II	III	I	II	III	I	II	III
1.	Decision tree	26	15	12	28	17	10	19		
2.	Classification rules	29	16	13	25	15	11	20		
3.	Corporate decision trees	27	13	10	26	11	8	16		
4.	Corporate classification rules	30	13	10	22	11	8	17		

## Conclusions

1. Reliability of classification became higher when the attribute “tumour height” was eliminated.

2. The digitized values of the reflectivity coefficient (low, medium, high) and the irregularity coefficient (regular, irregular) should be used. The best reliability of classification is achieved when the thresholds values equal to 70% and 93% for the reflectivity coefficients and the threshold value equal to 1.72 for the irregularity coefficient was selected.

3. The classifier constructed using the corporate decision trees has been found the best for classification of intraocular tumors.

4. Amount of classification errors decreases to 13%, when aberrant cases in the database were eliminated. Amount of classification errors have decreased to 8%, when tumors with prominence less than mm were eliminated from the database.

5. All classification algorithms have difficulties to recognize metastasis. This can be explained with small amount cases of these kind of the tumours in database and with a small height specific to metastasis. So, it is relevant to expand the tumours database and to continue the investigations.

## Reference

1. Verbeek A. M., Thijssen J. M., Cuyppers M. H. M. Echographic classification of intraocular tumours. *Acta Ophthalmologica*. 1994.. No.72. P. 416-422.

2. Verbeek A. M., Thijssen J. M., Osterveld B. J., Romijn R. L. Ultrasonic differentiation of intraocular melanomas: parameters and estimation methods. *Ultrasonimaging*. 1991. P. 27-55.
3. Mačiulis A., Kopustinskas A., Paunksnis A., Šebeliauskienė D. Echografinio vidinių akies auglių ir tinklainės degeneracinių pokyčių klasifikavimo parametrų analizė. *Elektronika ir elektrotechnika*. Kaunas: Technologija. 2002. Nr.5(40). P.76-80.
4. Jegelevičius D., Lukoševičius A., Paunksnis A., Barzdžiukas V. Application of data mining technique for diagnosis of posterior uveal melanoma. *Informatica*. 2002. No.4. P. 455-464.
5. Jegelevičius D., Lukoševičius A., Paunksnis A., Šebeliauskienė D. Parameterisation of ultrasonic echographic images for intraocular tumour differentiation. *Ultragarsas*. 2002. Nr.1. P. 50-56.

M. Žakauskas, A. Mačiulis, A. Kopustinskas, A. Paunksnis

## Vidinių akies darinių klasifikavimo parametrų ir būdo parinkimas

### Reziumė

Melanoma – tai melanocitinis neoplastinis auglys, galintis metastazuoti į plaučius, kepenis, kaulus. Vienam iš trijų ligonių gyslainės melanoma yra tiesioginė mirties priežastis, todėl šią patologiją būtina anksti diagnozuoti ir tinkamai gydyti. KMUK Akių ligų klinikos oftalmologijos laboratorijoje atliekami diagnostiniai akių tyrimai ultragarsu A/B režimais. Tyrimo metu gauti vaizdai keičiami į kompiuterinį formatą ir išsaugomi. Vėliau šie vaizdai analizuojami matematiniais bei statistiniais metodais. Tyrimui naudojami parametrai gaunami iš ultragarsinių vaizdų. Akies dariniai skirstomi į tris klases: melanomas, metastazes ir ne auglius. Darbo metu buvo tiriama atskirų klasifikavimo parametrų įtaka klasifikavimo tikslumui. Buvo naudojamos diskretizuotos atspindžio koeficiento (aukštas, vidutinis, žemas) ir nereguliarumo koeficiento (reguliarus, nereguliarus) vertės. Surastos optimalios šių koeficientų vertės.

Pateikta spaudai 2003 08 26

DOI: 10.5755/j01.u.49.4.8266